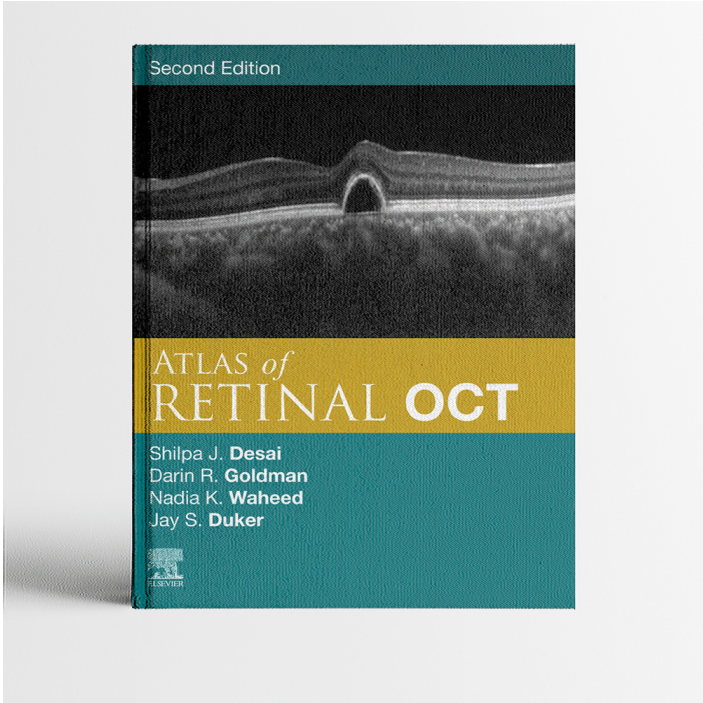


| | |
|---|---|
| **Peso** | 1 kg |
| **Dimensiones** | 28 × 22 × 2 cm |
| **Encuadernación** | Tapa blanda |
| **Páginas** | 272 |
| **Edición** | 2a edición |
| **Año** | 2023 |
| **Autor** | Jay S. Duker, Nadia K. Waheed |
| **Editorial** | Elsevier |
| **ISBN** | 9780323930437 |
| **Idioma** | Inglés |

## DESCRIPCIÓN DEL PRODUCTO

Unparalleled for aiding diagnosis of retinal disease and recording disease progression, Optical Coherence Tomography (OCT) remains one of the most significant advances in ophthalmology over the past 50 years. Atlas of Retinal OCT, 2nd Edition, provides expert guidance in making the most of this diagnostic tool with high-quality, oversized images that show precise detail and assist with rapid, accurate clinical decision making. Led by the same expert team of Drs. Jay S. Duker, Nadia K. Waheed, and Darin R. Goldman, and with the addition of new editor Dr. Shilpa J. Desai, this atlas remains your “go to reference source for OCT imaging of the retina. Now updated throughout to align with current practice, it covers a range of both common and rare disorders and presentations.

**Puntos clave del libro Atlas of Retinal OCT 2nd Edition.**

- Features more than 1,000 high-quality illustrations depicting the full spectrum of retinal diseases using OCT and OCTA scans, supported by clinical photos and ancillary imaging technologies.
- Contains new and updated image examples throughout—including new OCTA images with artifacts and key findings highlighted.
- Presents images as large as possible on the page with an abundance of arrows, pointers, and labels to guide you in pattern recognition and eliminate any uncertainty.

- Includes the latest high-resolution spectral domain OCT technology and new insights into OCT angiography technology to ensure you have the most up-to-date and highest quality examples available.
- Provides key feature points for each disorder, giving you the need-to-know OCT essentials for quick comprehension and rapid reference.
- An excellent diagnostic companion to Handbook of Retinal OCT: Optical Coherence Tomography, 2nd Edition.
- An eBook version is included with purchase. The eBook allows you to access all of the text, figures and references, with the ability to search, customize your content, make notes and highlights, and have content read aloud.

*» Más libros de Oftalmología*
*» Más libros de Retina y vítreo*
*» Más libros de Imagenología ocular*
*» Síganos en Facebook*

**Índice del libro Atlas of Retinal OCT 2nd Edition**

**PART 1: NORMAL OPTICAL COHERENCE TOMOGRAPHY**
Section 1: Normal Optic Nerve
1.1 Normal Optic Nerve
Section 2: Normal Retina
2.1 Time Domain OCT
2.2 Spectral Domain OCT
2.3 Swept Source OCT
Section 3: Normal Choroid
3.1 Normal Choroid
Section 4: Normal Vitreous
4.1 Normal Vitreous
Section 5: OCT: Artifacts and Errors
5.1 OCT: Artifacts and Errors
5.2 OCT Angiography Artifacts

**PART 2: ISOLATED MACULAR DISORDERS**
Section 6: Age-Related Macular Degeneration
6.1.1 Drusen
6.1.2 Geographic Atrophy
6.1.3 Isolated Pigment Epithelial Detachment
6.2.1 Type 1 Macular Neovascular Membrane
6.2.2 Type 2 Macular Neovascular Membrane
6.2.3 Type 3 Macular Neovascular Membrane
6.2.4 Subretinal Hemorrhage

6.2.5 Disciform Scar
6.2.6 Retinal Pigment Epithelial Tear
6.2.7 Polypoidal Choroidal Vasculopathy
Section 7: Vitreomacular Interface Disorders
7.1 Vitreomacular Adhesion
7.2 Vitreomacular Traction
7.3 Full-Thickness Macular Hole
7.4 Lamellar Macular Hole
7.5 Epiretinal Membrane
Section 8: Central Serous Chorioretinopathy
8.1 Central Serous Chorioretinopathy
Section 9: Myopic Degenerative Maculopathies
9.1 Myopic Choroidal Neovascular Membrane
9.2 Myopic Macular Schisis
9.3 Dome-Shaped Macula
9.4 Posterior Staphyloma
Section 10: Hydroxycholoroquine and Pentosan Toxicities
10.1 Hydroxychloroquine Toxicity
10.2 Pentosan Toxicity
Section 11: Vitelliform Macular Dystrophy
11.1 Vitelliform Dystrophy
Section 12: Macular Telangiectasia
12.1 Macular Telangiectasia
Section 13: Isolated Cystoid Macular Edema
13.1 Isolated Cystoid Macular Edema
Section 14: Other Disorders Affecting the Macular
14.1 Angioid Streaks
14.2 X-Linked Juvenile Retinoschisis
14.3 Oculocutaneous Albinism
14.4 Subretinal Perfluorocarbon

**PART 3: VASOOCCLUSIVE DISORDERS**
Section 15: Diabetic Retinopathy
15.1 Diabetic Macular Edema
15.2 Nonproliferative Diabetic Retinopathy
15.3 Proliferative Diabetic Retinopathy
Section 16: Retinal Venous Occlusive Disease
16.1 Branch Retinal Vein Occlusion
16.2 Central Retinal Vein Occlusion
Section 17: Retinal Arterial Occlusive Disease
17.1 Branch Retinal Artery Occlusion

17.2 Central Retinal Arterial Occlusion

**PART 4: UVEITIS AND INFLAMMATORY DISORDERS**
Section 18: Noninfectious Uveitis
18.1.1 Birdshot Retinochoroidopathy
18.1.2 Acute Posterior Multifocal Placoid Pigment Epitheliopathy
18.1.3 Multiple Evanescent White Dot Syndrome
18.1.4 Serpiginous Choroiditis
18.1.5 Multifocal Choroiditis and Panuveitis and Punctate Inner Choroidopathy
18.2 Vogt-Koyanagi-Harada Disease
18.3 Sympathetic Ophthalmia
Section 19: Infectious Uveitis
19.1 Toxoplasmic Chorioretinitis
19.2 Acute Syphilitic Posterior Placoid Chorioretinitis
19.3 Tuberculosis
19.4 Posterior Scleritis
19.5 Candida Chorioretinitis
19.6 Acute Retinal Necrosis Syndrome

**PART 5: RETINAL AND CHOROIDAL TUMORS**
Section 20: Choroidal Tumors
20.1 Choroidal Nevus
20.2 Choroidal Melanoma
20.3 Solitary Choroidal Hemangioma
Section 21: Retinal Tumors
21.1 Retinal Capillary Hemangioma
Section 22: Retinal Pigment Epithelium Tumors
22.1 Simple Hamartoma of the RPE
22.2 Combined Hamartoma of the Retina and RPE
Section 23: Metastatic Choroidal Tumors
23.1 Choroidal Metastases

**PART 6: TRAUMA**
Section 24: Mechanical Trauma
24.1 Valsalva Retinopathy
Section 25: Photic Maculopathy
25.1 Laser Maculopathy
25.2 Solar Maculopathy

**PART 7: INHERITED RETINAL DEGENERATIONS**
Section 26: Retinal Dystrophies
26.1 Retinitis Pigmentosa

26.2 Stargardt Disease
26.3 Best Disease
26.4 Cone Dystrophy
26.5 Malattia Leventinese (Doyne's Honeycomb Retinal Dystrophy)
26.6 Central Areolar Choroidal Dystrophy

**PART 8: VITREOUS DISORDERS**
Section 27: Posterior Vitreous Detachment
27.1 Stages of Posterior Vitreous Detachment
Section 28: Asteroid Hyalosis
28.1 Asteroid Hyalosis
Section 29: Vitreous Hemorrhage
29.1 Vitreous Hemorrhage
Section 30: Vitreous Inflammation
30.1 Vitreous Inflammation

**PART 9: MISCELLANEOUS RETINAL DISORDERS**
Section 31: Peripheral Retinal Abnormalities
31.1 Tractional Retinal Detachment
31.2 Rhegmatogenous Retinal Detachment
31.3 Bullous Retinoschisis
31.4 Lattice Degeneration
31.5 Myelinated Nerve Fiber Layer