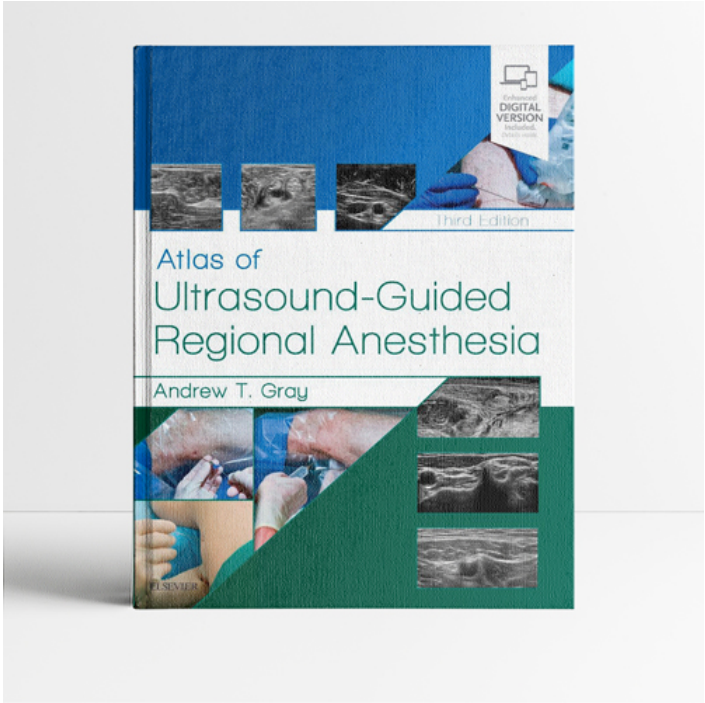

Peso	1.4 kg
Dimensiones	21.6 × 27.6 × 2 cm
Encuadernación	Tapa dura
Páginas	412
Año	2018
Edición	3era edición
Autor	Andrew T. Gray
Editorial	Elsevier
ISBN	9780323509510
Idioma	Inglés

DESCRIPCIÓN DEL PRODUCTO

Step-by-step videos and images, board-style review questions, and coverage of new blocks make this highly respected title a must-have reference for clinical practice. Written by Andrew T. Gray, MD, PhD, one of the pioneers of the use of ultrasound to guide needle placement, Atlas of Ultrasound-Guided Regional Anesthesia, 3rd Edition, shows you how to safely and effectively use the latest methods and applications of this technique.

Puntos clave

- Board-style review questions found on the Expert Consult eBook version test your knowledge and help you prepare for the ABA exam.
- Helps ensure correct needle placement with numerous 3-D and long-axis views that clearly depict surrounding structures.

Índice de Atlas of Ultrasound-Guided Regional Anesthesia 3rd edition

Section 1 - Introduction to Ultrasound Imaging
1 Ultrasound
2 Speed of Sound

3 Attenuation
4 Reflection
5 Beam Width (Slice Thickness)
6 Anisotropy
7 Spatial Compound Imaging
8 Doppler Imaging
9 Ultrasound Transducers
10 Transducer Manipulation
11 Needle Imaging
12 Approach and Techniques
13 Sonographic Signs of Successful Injections
14 Ultrasound-Guided Continuous Peripheral Nerve Blocks
15 Three-Dimensional Ultrasound

Section 2 - Structures
16 Anatomic Structures
17 Skin and Subcutaneous Tissue
18 Peripheral Nerves
19 Muscle
20 Tendons and Ligaments
21 Arteries
22 Veins
23 Bone
24 Pleura
25 Peritoneum

Section 3 - Upper Extremity Blocks
26 Lymph Nodes
27 Supraclavicular Nerve Block
28 Interscalene and Supraclavicular Blocks
29 Phrenic Nerve Imaging
30 Dorsal Scapular Nerve Imaging
31 Suprascapular Nerve Block (Anterior Approach above the Clavicle)
32 Infraclavicular Block
33 Axillary Block
34 Musculocutaneous Nerve Block
35 Forearm Blocks
36 Radial Nerve Block
37 Median Nerve Block
38 Ulnar Nerve Block

Section 4 - Lower Extremity Blocks

39 Lateral Femoral Cutaneous Nerve Block
40 Fascia Iliaca Block
41 Femoral Nerve Block
42 The Adductor Canal Block
43 Obturator Nerve Block
44 Sciatic Nerve Block
45 Anterior Sciatic Nerve Block
46 Popliteal Block
47 Posterior Femoral Cutaneous Nerve (PFCN) Block
48 Ankle Block
49 Saphenous Nerve Block in the Leg
50 Deep Peroneal Nerve Block
51 Superficial Peroneal Nerve Block
52 Sural Nerve Block
53 Tibial Nerve Block

Section 5 - Trunk Blocks
54 Intercostal Nerve Block
55 Pectoral Nerve Block (the Pecs Block)
56 Transversus Thoracis Muscular Plane Block
57 Rectus Sheath Block
58 Ilioinguinal and Iliohypogastric Nerve Blocks
59 Transversus Abdominis Plane (TAP) Blocks
60 Quadratus Lumborum Blocks
61 Thoracic Paravertebral Block
62 Pudendal Nerve Block in Children
63 Neuraxial Block
64 Caudal Epidural Block

Section 6 - Head and Neck Blocks
65 Supraorbital Nerve Block
66 Mental Nerve Block
67 Superior Laryngeal Nerve Block
68 Transtracheal Block
69 Greater Occipital Nerve Block
70 Lesser Occipital Nerve Block
71 Great Auricular Nerve Block
72 Cervical Plexus Block
73 Stellate Ganglion Block (Cervicothoracic Sympathetic Ganglion Block)

Section 7 - Safety Issues
74 Safety: Practical Techniques to Prevent Complications During Ultrasound-Guided Nerve Blocks

75 Regional Anesthesia in Resource-Constrained Environments

Appendix 1. Self-Assessment Questions: Text
Appendix 2. Self-Assessment Questions: Images
Appendix 3. Advanced Self-Assessment Questions: Text
Appendix 4. Advanced Self-Assessment Questions: Images

Más de Anestesiología »
Síganos en Facebook »