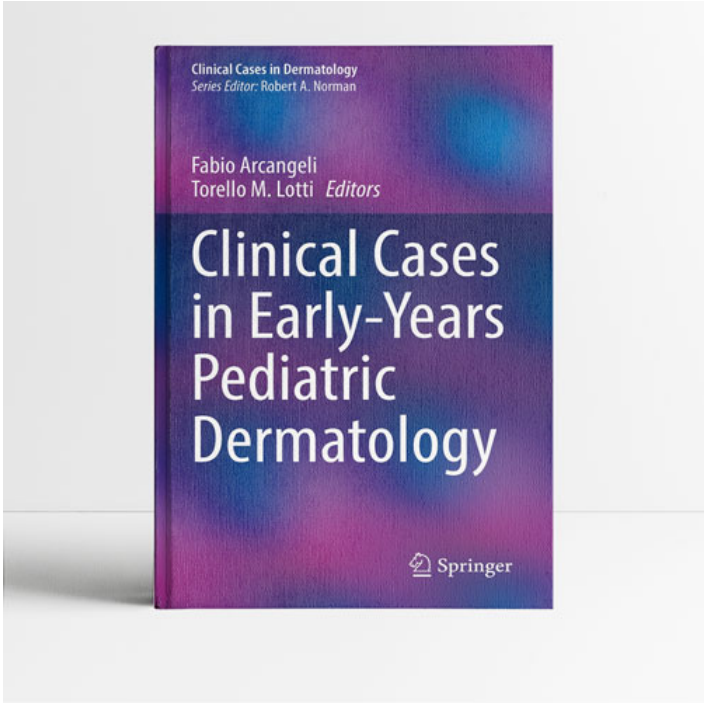

Peso	0.25 kg
Dimensiones	15 × 23 × 1 cm
Encuadernación	Tapa blanda
Páginas	104
Año	2022
Edición	1era edición
Autor	Fabio Arcangeli, Torello M. Lotti
Editorial	Springer
ISBN	9783030890889

DESCRIPCIÓN DEL PRODUCTO

This book is a concise practical guide designed to facilitate the clinical decision-making process in the management of pediatric skin disease. Dermatologists and general pediatricians who offer primary care to children must be knowledgeable in managing dermatological problems, and this title provides insightful reviews of a number of common and rare dermatologic cases. Clinical cases are a key component in modern medical education, assisting the trainee or recertifying clinician to work through unusual scenarios using best practice techniques. Pediatric dermatology is a particularly important discipline in this regard since it is a highly visual subject requiring the reader to describe often very subtle differences in the presentation of patients and define accurately the diagnostic and management criteria on which to base their clinical decision-making.

Clinical Cases in Early-Years Pediatric Dermatology concisely covers how to approach diagnosing and managing patients between ages 2 through 5 years. Each chapter focuses on a particular case and emphasizes how to make an appropriate choice when deciding which diagnostic tool or management strategy would be most suitable. Potential complications are detailed and management tips provided to enable the reader to develop a deep understanding of how approach the care of these patients within their day-to-day clinical practice. This book therefore represents an ideal up-to-date resource for all practitioners who encounter these cases as part of their everyday practice.

Índice Clinical Cases in Early-Years Pediatric Dermatology 1st edition

1. 5 Year Old with Fever and Perioral and Periorbital Erythema
2. A Child with High Fever, Rash, Chapped Lips and Conjunctival Injection
3. A Five-Year-Old Girl with Erythematous Papules on Cheek
4. A Four- Year- Old Girl with Otalgia
5. A Little Boy with Facial Erythema
6. A Pediatric Case with Erythematous Plaques and Palmoplantar Keratoderma
7. A Rare Case of Xeroderma Pigmentosum in 3 Years Old Child with Squamous Cell Carcinoma
8. A Young Boy with Fever and Rash
9. A Young Child with Vesiculopustular Eruptions and Mucosal Erosion
10. A Young Girl with an Erythematous Lesion on the Lower Eyelid Region
11. Chronic Bullous Disease of Childhood with Hypertrophic Scars Complications
12. Chronic Cutaneous Lesions of Unknown Origin
13. Diffuse Pruritic Lesions in a 3-Years-Old Child
14. Fournier Gangrene in 3 Years Old Patient with B Cell Acute Lymphoblastic Leukemia
15. Itching Eyelids in a Child with Atopic Dermatitis
16. Liver Involvement in Langerhans Cell Histiocytosis
17. Localized Scaly Hair Loss
19. Papular Lesions Arranged in Annular Configuration in Children
19. Pustular Plaque on a Girl's Scalp
20. Red and Swelling Scrotum as an Early Clue for Diagnosis

Más de Dermatología »
Síguenos en Facebook »