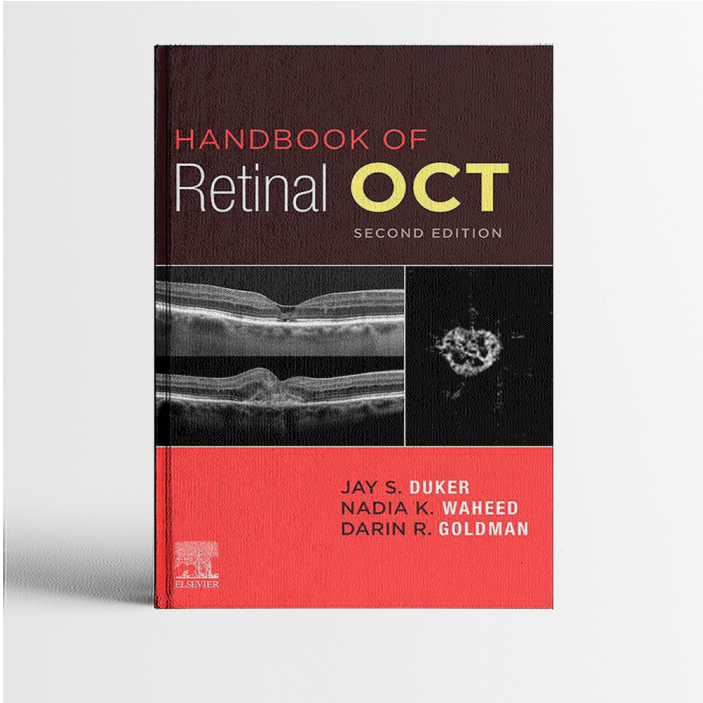


| | |
|---|---|
| **Peso** | 0.5 kg |
| **Dimensiones** | 23 × 16 × 2 cm |
| **Encuadernación** | Tapa blanda |
| **Páginas** | 272 |
| **Edición** | 2a edición |
| **Año** | 2023 |
| **Autor** | Jay S. Duker, Nadia K. Waheed |
| **Editorial** | Elsevier |
| **ISBN** | 9780323757720 |
| **Idioma** | Inglés |

## DESCRIPCIÓN DEL PRODUCTO

Arguably the most important ancillary test available to ophthalmologists worldwide, optical coherence tomography (OCT) has revolutionized the field, and now includes angiographic evaluations (OCTA) that provide vascular flow data without eye injection. Handbook of Retinal OCT is an easy-to-use, high-yield guide to both OCT and OCTA imaging for practitioners at any stage of their career. Highly templated, concise, and portable, this revised edition helps you master the latest imaging methods used to evaluate retinal disease, uveitis, and optic nerve disorders.

**Puntos clave del libro Handbook of Retinal OCT 2nd Edition**

- Helps all health professionals with an interest in OCT to better and more quickly interpret OCT imaging, offering quick, highly visual guidance for evaluating age-related macular degeneration, diabetic retinopathy, retinal vein occlusion, and much more.
- Provides quick answers with bulleted, templated chapters, each focused on one specific diagnosis or group of diagnoses with a particular OCT appearance.
- Demonstrates how the full spectrum of diseases presents through approximately 400 illustrations, including the highest-quality spectral-domain OCT images available and more than 50 new OCTA images.
- Includes five new chapters covering optic nerve disease with retinal findings, pachychoroid diseases, paracentral

acute middle maculopathy (PAMM), auto-immune retinopathies, and primary uveal lymphoma.
- Offers clear visual guidance on image patterns with multiple arrows and labels throughout to highlight key details of each disease.
- Enhanced eBook version included with purchase. Your enhanced eBook allows you to access bonus images plus all of the text, figures, and references from the book on a variety of devices.

*» Más libros de Oftalmología*
*» Más libros de Retina*
*» Síganos en Facebook*

**Índice del libro Handbook of Retinal OCT 2nd Edition**

Part 1: Introduction to OCT
Section 1: OCT: What It Is
1.1 Scanning Principles
1.2 Basic Scan Patterns and OCT Output
Section 2: Data and Interpretation
2.1 OCT Interpretation
Section 3: OCT Artifacts
3.1 Artifacts on SD-OCT and OCTA
Section 4: Normal Retinal Anatomy and Basic Pathologic Appearances
4.1 Normal Retinal Anatomy and Basic Pathologic Appearances

Part 2: Optic Nerve Disorders
Section 5: Optic Nerve Disorders
5.1 Basic Optic Nerve Scan Patterns and Output

Part 3: Macular Disorders
Section 6: Dry Age- Related Macular Degeneration
6.1 Dry Age-Related Macular Degeneration
Section 7: Wet Age-Related Macular Degeneration
7.1 Wet Age-Related Macular Degeneration
Section 8: Macular Pathology Associated with Myopia
8.1 Posterior Staphyloma
8.2 Myopic Choroidal Neovascular Membrane
8.3 Myopic Macular Schisis
8.4 Dome-Shaped Macula
8.5 Myopic Tractional Retinal Detachment
Section 9: Vitreomacular Interface Disorders
9.1 Pachychoroid Syndromes

9.2 Vitreomacular Adhesion and Vitreomacular Traction
9.3 Full Thickness Macular Hole
9.4 Lamellar Macular Hole (LMH)
9.5 Epiretinal Membrane
Section 10: Miscellaneous Causes of Macular Edema
10.1 Postoperative Cystoid Macular Edema
10.2 Macular Telangiectasia
10.3 Uveitis
Section 11: Miscellaneous Macular Disorders
11.1 Central Serous Chorioretinopathy
11.2 Hydroxychloroquine Toxicity
11.3 Pattern Dystrophy
11.4 Oculocutaneous Albinism
11.5 Subretinal Perflourocarbon
11.6 X-linked Juvenile Retinoschisis

Part 4: Vaso-Occlusive Disorders
Section 12: Diabetic Retinopathy
12.1 Non-proliferative Diabetic Retinopathy
12.2 Nonproliferative Diabetic Retinopathy with Macular Edema
12.3 Proliferative Diabetic Retinopathy
Section 13: Retinal Vein Occlusion
13.1 Branch Retinal Vein Occlusion (BRVO)
13.2 Central Retinal Vein Occlusion (CRVO)
Section 14: Retinal Artery Occlusion
14.1 Branch Retinal Artery Occlusion
14.2 Central Retinal Artery Occlusion
14.3 Cilioretinal Artery Occlusion
14.4 Paracentral Acute Middle Maculopathy

Part 5: Inherited Retinal Degenerations
Section 15: Inherited Retinal Degenerations
15.1 Retinitis Pigmentosa
15.2 Stargardt Disease
15.3 Best Disease
15.4 Cone Dystrophy

Part 6: Uveitis and Inflammatory Diseases
Setion 16: Posterior Non-Infectious Uveitis
16.1 Multifocal Choroditis
16.2 Birdshot Chorioretinopathy
16.3 Serpiginous Choroiditis

16.4 Vogt-Koyanagi-Harada Disease
16.5 Sympathetic Opthalmia
16.6 Posterior Scleritis
Section 17: Posterior Infection Uveitis
17.1 Toxoplasma Chorioretinitis
17.2 Tuberculosis
17.3 Acute Syphilitic Posterior Placoid Chorioretinitis
17.4 Candida Albicans Endogenous Endophthalmitis
17.5 Acute Retinal Necrosis Syndrome

Part 7: Trauma
Section 18: Physical Trauma
18.1 Commotio Retinae
18.2 Choroidal Rupture and Subretinal Hemorrhage
18.3 Valsalva Retinopathy
Section 19: Photothermal, Photomechanical, and Photochemical Trauma
19.1 Laser Injury (Photothermal and Photomechanical)
19.2 Solar Maculopathy

Part 8: Tumors
Section 20: Choroidal Tumors
20.1 Choroidal Nevus
20.2 Choroidal Melanoma
20.3 Choroidal Hemangioma
Section 21: Retinal Tumors
21.1 Retinal Capillary Hemangioma
21.2 Retinoblastoma
Section 22: Other Tumors
22.1 Metastatic Choroidal Tumor
22.2 Vitreoretinal Lymphoma
22.3 Primary Uveal Lymphoma

Part 9: Peripheral Retinal Abnormalities
Section 23: Retinal Detachment
23.1 Retinal Detachment
Section 24: Retinoschisis
24.1 Retinoschisis
Section 25: Peripheral Lattice Degeneration
25.1 Peripheral Lattice Degeneration