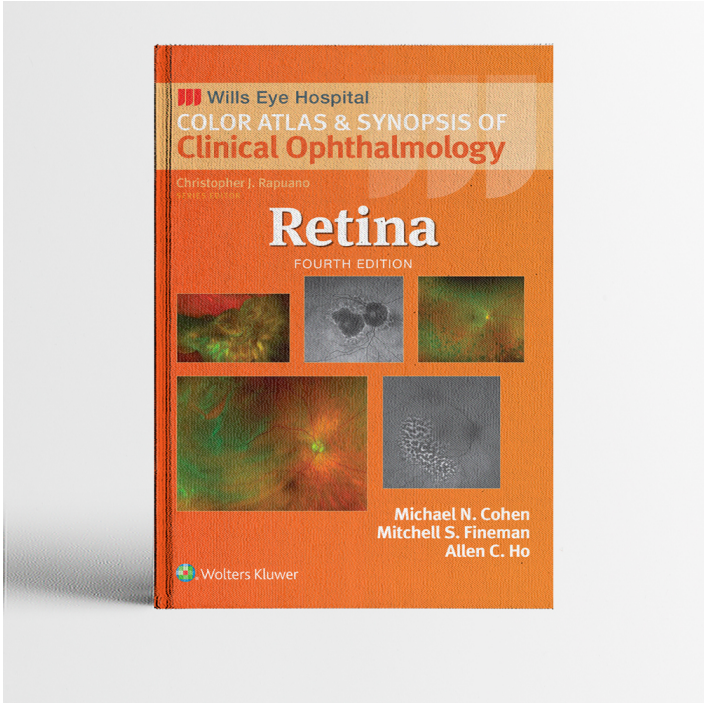

Peso	0.8 kg
Dimensiones	23 × 15 × 3 cm
Encuadernación	Tapa blanda
Páginas	480
Edición	4a edición
Año	2024
Autor	Mitchell S. Fineman
Editorial	Wolters Kluwer
ISBN	9781975215149
Idioma	Inglés

DESCRIPCIÓN DEL PRODUCTO

Developed at Philadelphia's world-renowned Wills Eye Hospital, the Color Atlas and Synopsis of Clinical Ophthalmology series covers the most clinically relevant aspects of ophthalmology in a highly visual, easy-to-use format. Vibrant, full-color photos and a consistent outline structure present a succinct, high-yield approach to the seven topics covered by this popular series: Cornea, Retina, Glaucoma, Oculoplastics, Neuro-Ophthalmology, Pediatrics, and Uveitis. This in-depth, focused approach makes each volume an excellent companion to the larger Wills Eye Manual as well as a practical stand-alone reference for students, residents, and practitioners in every area of ophthalmology.

Puntos clave del libro Retina 4th Edition.

- The updated Retina volume includes:
  - Expert, state-of-the-art guidance on the diagnosis and management of vitreoretinal diseases, ideal for practicing ophthalmologists, retinal specialists, fellows, and residents
  - More than 400 high-quality images, including higher resolution spectral domain OCTs, high resolution digital fundus photos, and widefield imaging
- An easy-to-use format that covers Epidemiology and Etiology, History, Physical Examination, Differential

Diagnosis, Laboratory and Special Examinations, Diagnosis, Prognosis, and Management

» Más libros de Oftalmología
» Más libros de Retina
» Síganos en Facebook

Índice del libro Retina 4th Edition

Dedication
Editors
Contributors
About the Series
Preface
Acknowledgments
Chapter 1 Age-Related Macular Degeneration
Introduction
Nonexudative Age-Related Macular Degeneration
Neovascular Age-Related Macular Degeneration
Chapter 2 Macular Diseases
Macular Epiretinal Membrane
Idiopathic Macular Hole
Disorders of the Vitreomacular Interface
Vitreomacular Adhesion
Vitreomacular Traction
Cystoid Macular Edema
Polypoidal Choroidal Vasculopathy
Degenerative Myopia
Angioid Streaks
Central Serous Retinopathy
Choroidal Folds
Hypotony Maculopathy
Chapter 3 Diabetic Retinopathy
Diabetic Retinopathy
Nonproliferative Diabetic Retinopathy
Proliferative Diabetic Retinopathy
Diabetic Papillopathy
Chapter 4 Retinal Vascular Disease
Cotton-Wool Spots

Hypertensive Retinopathy
Cilioretinal Artery Obstruction (Occlusion)
Branch Retinal Artery Obstruction (Occlusion)
Central Retinal Artery Obstruction (Occlusion)
Acute Ophthalmic Artery Obstruction (Occlusion)
Combined Central Retinal Artery and Vein Obstruction (Occlusion)
Ocular Ischemic Syndrome
Branch Retinal Vein Obstruction (Occlusion)
Central Retinal Vein Obstruction (Occlusion)
Retinal Arterial Macroaneurysm
Idiopathic Juxtafoveal (Parafoveal) Telangiectasis
Sickle Cell Retinopathy
Radiation Retinopathy
Lipemia Retinalis
Chapter 5 Retinal Degenerations and Dystrophies
Best Disease
Cone Dystrophy
Pattern Dystrophy
Stargardt Disease
Choroideremia
Gyrate Atrophy
Congenital Stationary Night Blindness
Fundus Albipunctatus
Oguchi Disease
Albinism
Retinitis Pigmentosa
Systemic Diseases Associated With Retinitis Pigmentosa
Carcinoma-Associated Retinopathy Syndrome
Chapter 6 Retinal and Choroidal Tumors
Astrocytic Hamartoma
Retinoblastoma
Retinal Capillary Hemangioblastoma
Retinal Cavernous Hemangioma
Congenital Hypertrophy of the Retinal Pigment Epithelium
Combined Hamartoma of the Retina and Retinal Pigment Epithelium
Choroidal Nevus
Choroidal Melanoma
Optic Disc Melanocytoma
Choroidal Melanocytoma
Choroidal Metastasis
Choroidal Hemangioma

Primary Vitreoretinal Lymphoma
Choroidal Lymphoma
Choroidal Osteoma
Choroidal Granuloma
Vasoproliferative Retinal Tumor
Chapter 7 Congenital and Pediatric Retinal Diseases
Retinopathy of Prematurity
Incontinentia Pigmenti
Familial Exudative Vitreoretinopathy
Coats Disease
Chorioretinal Coloboma
Persistent Fetal Vasculature
X-Linked Retinoschisis
Leber Congenital Amaurosis
Chapter 8 Traumatic and Toxic Retinopathies
Commotio Retinae
Choroidal Rupture
Avulsed Vitreous Base
Solar Maculopathy
Valsalva Retinopathy
Shaken Baby Syndrome
Terson Syndrome
Purtscher Retinopathy
Traumatic Macular Hole
Chorioretinitis Sclopetaria
Intraocular Foreign Body
Dislocated Lens
Talc Retinopathy
Chloroquine or Hydroxy-Chloroquine Retinopathy
Thioridazine Retinopathy
Pentosan Polysulfate Sodium Maculopathy
Mitogen-Activated Protein Kinase Inhibitor–Associated Retinopathy
Ocular Decompression Retinopathy
Chapter 9 Peripheral Retinal Disease
Retinal Break or Tear
Rhegmatogenous Retinal Detachment
Proliferative Vitreoretinopathy
Lattice Degeneration
Vitreoretinal Tuft and Meridional Fold
Cobblestone Degeneration
Peripheral Grouped Pigmentation

Degenerative Retinoschisis
Exudative Retinal Detachment
Choroidal Detachment