Qi
Enhanced
DIGITAL
VERSION
Induded

Yen E Joffe's

# REPRODUCTIVE ENDOCRINOLOGY

*Physiology Pathophysiology, and Clinical Management*

STRAUSS • BARBIERI • DOKRAS • WILLIAMS • WILLIAMS



ELSEVIER

Ninth Edition

# Contents

Video Contents xv

## PART 1
## The Fundamentals of Reproduction 1

1. Neuroendocrinology of Reproduction 1
*Christopher R. McCartney and John C. Marshall*

2. The Gonadotropin Hormones and Their Receptors 23
*Prema Narayan, Alfredo Ulloa-Aguirre, and James A. Dias*

3. Prolactin in Human Reproduction 56
*Nicholas A. Tritos*

4. Steroid Hormones and Other Lipid Molecules Involved in Human Reproduction 73
*Jerome F. Strauss III, Emanuela Ricciotti, and Garret A. FitzGerald*

5. Steroid Hormone Action 110
*Shannon Whirledge and John A. Cidlowski*

6. Growth Factors and Reproduction 125
*Diana Monsivais and Stephanie A. Pangas*

7. Neuroendocrine Control of the Menstrual Cycle 142
*Janet E. Hall*

8. The Ovarian Life Cycle 158
*Jerome F. Strauss III and Carmen J. Williams*

9. Meiosis, Fertilization, and Preimplantation Embryo Development 188
*Carmen J. Williams and Karen Schindler*

10. Structure, Function, and Evaluation of the Female Reproductive Tract 217
*Andrew M. Kelleher, Leah H. Bressler, Steven L. Young, and Thomas E. Spencer*

11. Endocrinology of Human Pregnancy and Fetal-Placental Neuroendocrine Development 254
*Sam Mesiano*

12. The Breast 277
*Robert Barbieri*

13. The Hypothalamo-Pituitary Unit, Testis, and Male Accessory Organs 285
*Peter Y. Liu*

14. Menopause and Aging 300
*Roger A. Lobo and Yousin Suh*

15. Male Reproductive Aging 338
*Peter J. Snyder*

16. Immunology and Reproduction 345
*Aleksandar K. Stanic, William Hanna Kutteh, Kassie Bollig, and Danny J. Schust*

## PART 2
## Pathophysiology and Therapy: Pediatric, Adolescent, and Adult 365

17. Differences of Sex Development 365
*Emmanuèle C. Délot and Eric Vilain*

18. Puberty: Gonadarche and Adrenarche 395
*Aviva B. Sopher, Sharon E. Oberfield, and Selma Feldman Witchel*

19. Nutrition and Reproduction 449
*Nanette Santoro, Alex J. Polotsky, Thanh-Ha Luu, Melissa Menezes, Jessica Rieder, Laxmi A. Kondapalli, and Cassandra Roeca*

20. Environmental Factors and Reproduction 461
*Linda C. Giudice, Marya G. Zlatnik, Thalia R. Segal, and Tracey J. Woodruff*

21. Physiological and Pathophysiological Alterations of the Neuroendocrine Components of the Reproductive Axis 475
*Ralf Nass and William S. Evans*

22. Polycystic Ovary Syndrome and Hyperandrogenic States 516
*R. Jeffrey Chang, Anuja Dokras, and Daniel A. Dumesic*

23. Female Infertility 548
*Paula C. Brady and Robert Barbieri*

24. Male Infertility 575
*Peter N. Schlegel*

25. Endocrine Disturbances Affecting Reproduction 587
*Xin He, Alice Y. Chang, and Richard J. Auchus*

26. Benign Uterine Diseases and Dysfunction 601
*Lauren Kendall Rauchfuss and Elizabeth A. Stewart*

27. Endometriosis 619
*Serdar E. Bulun*

28. Recurrent Pregnancy Loss 650
*Jenna Turocy and Zev Williams*

29. Endocrine Diseases of Pregnancy 665
*Molly R. Siegel and Andrea G. Edlow*

30. Hormone-Responsive Cancers 712
*Rinath Jeselsohn and Alok K. Tewari*

31. Transgender Hormonal Treatment 735
*Tamar Reisman and Joshua D. Safer*

## PART 3
## Reproductive Technologies 742

32. Evaluation of Hormonal Status 742
*Enrico Carmina, Frank Z. Stanczyk, and Rogerio A. Lobo*

**33.** Pelvic Imaging in Reproductive Endocrinology 772
*Misty Blanchette Porter and Steven Robert Goldstein*

**34.** Medical Approaches to Ovarian Stimulation for Infertility 813
*Richard S. Legro and Bart C.J.M. Fauser*

**35.** Assisted Reproduction: Clinical Practice 842
*Daniel J. Kaser, Elizabeth S. Ginsburg, and Catherine Racowsky*

**36.** Gamete and Embryo Manipulation 876
*Mitchell Rosen, Eduardo Hariton, Philip Marsh, Jerrine Morris, Giovanna Olivera, Andrew Runge, Molly Quinn, Salustiano Ribeiro,* and *Rhodel Simbulan*

**37.** Fertility Preservation 907
*Francesca E. Duncan, Robert Brannigan, Jill P. Ginsberg, and Clarisa R. Gracia*

**38.** Emerging Technologies: *In Vitro*-Derived Germ Cells and Gametogenesis 935
*Monica M. Laronda, Takehiko Ogawa, Sierra Goldsmith, Sherman J. Silber, Amander T. Clark, Katsuhiko Hayashi, and Kyle E. Orwig*

**39.** Emerging Technologies: Genetic Interventions in the Human Germ Line: Mitochondrial Replacement and Gene Editing 948
*Dieter Egli*

**40.** Emerging Technologies: Uterus Transplantation 955
*Kathleen O'Neill*

**41.** Contraception 970
*Andrea H. Roe and Courtney A. Schreiber*

Index 985

# Video Contents


**17.1** Developmental anomalies of the uterus and vagina: classification and treatment

**26.1** Overview of the FIGO classification of uterine leiomyoma and the various operative techniques used for myomectomy, including hysteroscopic myomectomy, laparoscopic myomectomy, robotic-assisted myomectomy, and open myomectomy

**26.2** Overview of different endometrial pathologies and the various hysteroscopic techniques employed for their resection, including hysteroscopic myomectomy, hysteroscopic metroplasty, and hysteroscopic lysis of adhesions

**27.1** Descriptions of lesion types, how to report endometriosis findings, and the various surgical management options for each endometriosis scenario

**33.1** Sonohysterography (SHG) dynamic imaging of performance of an SHG with a polyp or myoma

**33.2** Hysterosalpingo-contrast sonography video

**33.3** Dynamic ultrasound demonstrating anterior and posterior cul-de-sac adhesions relative to deeply invasive endometriosis (sliding sign)

**36.1** The IVF laboratory: management and technologies

**37.1** Mini laparotomy, ovarian tissue preparation on the bench prior to vitrification, and ovarian tissue transplantation

PART I

The Fundamentals of Reproduction

# 1 Neuroendocrinology of Reproduction

*Christopher R. McCartney and John C. Marshall*

## OUTLINE

**CENTRAL CONTROL OF REPRODUCTION**

**NEUROENDOCRINOLOGY: THE INTERFACE BETWEEN NEUROBIOLOGY AND ENDOCRINOLOGY**

- Anatomy of the Reproductive Hypothalamic-Pituitary Axis
- Gonadotropin-Releasing Hormone: The Final Common Pathway for the Central Control of Reproduction
- Neuronal Inputs Into Gonadotropin-Releasing Hormone Neurons
- Gonadotropin-Releasing Hormone Pulse Generator
- Gonadotropin-Releasing Hormone Secretion During Development and in Adulthood
- Physiologic Development of Reproductive Neuroendocrine Function
- Patterns of Pulsatile Gonadotropin-Releasing Hormone Secretion in Adults
- Feedback Regulation of Gonadotropin-Releasing Hormone and Gonadotropin Secretion
- Reproductive Neuroendocrine Adaptations in Settings of Reduced Energy Availability, Stress, and Lactation
- Interface Between Reproductive Neuroendocrine Function and Energy Availability
- Impact of Stress on Reproductive Neuroendocrine Function
- Lactation and Reproductive Neuroendocrine Function
- Miscellaneous Physiologic Influences on Gonadotropin-Releasing Hormone Secretion

## CENTRAL CONTROL OF REPRODUCTION

Successful reproduction is essential to the survival of a species. The reproductive system represents a highly complex functional organization of diverse tissues and signaling pathways that, when properly functioning, ensures a number of key endpoints. The most important of these are the adequate production and development of gametes (ova and sperm), successful delivery of gametes for fertilization, and physiologic preparation for possible pregnancy in women. Neuroendocrine systems are the principal drivers of reproductive function in both men and women. In particular, hypothalamic gonadotropin-releasing hormone (GnRH) is the primary—if not exclusive—feedforward stimulatory signal to gonadotrope cells of the anterior pituitary, which induces the synthesis and secretion of both luteinizing hormone (LH) and follicle-stimulating hormone (FSH). Together, these two gonadotropins direct the primary functions of the reproductive axis: gamete development and gonadal sex steroid synthesis.

Given its critical importance to a species, the reproductive system must be robust, continuing to function properly in the face of various physiologic perturbations. In contrast, in settings of marked physiologic stress (e.g., significantly reduced energy availability), mechanisms that temporarily limit fertility—the teleological outcome of which is metabolically expensive in women—are biologically advantageous for the individual and, ultimately, the species. Appropriate function (or quiescence) of the reproductive system is governed by a number of intricate relationships. For example, feedback signals from the gonads (e.g., circulating sex steroid concentrations) communicate the status of gonadal function to the hypothalamic-pituitary axis; these signals in turn influence GnRH and gonadotropin output, rendering a coordinated and tightly regulated feedback system that maintains gonadal function within narrow limits. The reproductive system also has extensive interactions with other neuroendocrine systems, such as those involved with energy balance and adaptations to stress. The reproductive neuroendocrine system integrates these myriad feedback signals, and the GnRH-secreting neuronal network represents the final common pathway for the central control of reproduction. Thus the regulation of GnRH secretion represents a major focus of reproductive neuroendocrinology.

Much of our understanding of reproductive neuroendocrinology has emerged from the study of rodents, ruminants, and nonhuman primates, largely reflecting the ethical boundaries inherent to human research. Because many neurobiological principles are similar among all mammals, these animal studies continue to be indispensable. Nonetheless, certain aspects of reproductive neuroendocrinology may differ markedly among species. Thus, when available, human data will be prioritized throughout this chapter, but animal studies will also be discussed when appropriate—emphasizing nonhuman primate studies when available—recognizing that specific findings may or may not be generalizable to humans. The reader is referred to Chapters 2, 7, 13, 18, and 21 for additional discussion of neuroendocrine physiology and pathophysiology related to reproduction.

## NEUROENDOCRINOLOGY: THE INTERFACE BETWEEN NEUROBIOLOGY AND ENDOCRINOLOGY

Endocrinology is the study of cell-to-cell signaling that occurs via specific chemicals (hormones) traveling through the bloodstream to influence remote targets. The term "neuroendocrinology" refers to the involvement of the central nervous system (CNS) in this process, particularly the hypothalamus. This field of study has traditionally focused on hypothalamic neuron-derived factors that influence various target tissues either directly, as with the hormones of the neurohypophysis, or indirectly, as with hypothalamic releasing factors that control anterior pituitary hormone secretion. Neuroendocrine systems direct a wide variety of critical biologic processes, such as growth and development, energy and fluid homeostasis, responses to stress, and reproduction.

Neurons are highly specialized, morphologically diverse cells that transmit information via electrical impulses called action potentials. Neurons have a cell body (perikaryon) containing the

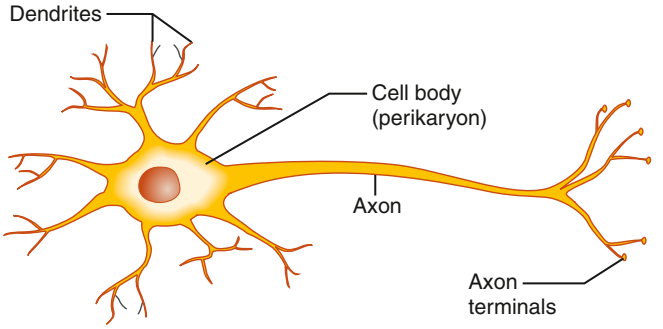


**Fig. 1.1** Morphologic components of a neuron.

cell nucleus, mitochondria, and synthetic organelles. Neurons also have cell processes that participate in the reception and delivery of electrical impulses (Fig. 1.1). Dendrites are short processes—often extensively branched to increase surface area—that typically receive information by way of afferent electrical impulses from other neurons. The axon is a single neuronal extension that generally transmits efferent electrical impulses away from the cell body via a process called *neuronal firing*. However, GnRH neuron fibers extending from the cell body to the median eminence (the location of GnRH release) in mice demonstrate characteristics of both axons and dendrites and thus have been called dendrons.[1]

In unstimulated neurons, the inner portion of the neuronal membrane is negatively charged compared with the outer membrane surface; this *resting membrane potential* is typically between −50 and −75 mV in GnRH neurons. Such electrical polarization reflects transmembrane ionic differences, which are maintained by protein channels that govern transmembrane passage of specific ions (e.g., sodium, potassium, chloride). Regulated changes of transmembrane ion differences may cause the membrane potential to become more or less negative (hyperpolarization and depolarization, respectively). Depolarization to a certain threshold results in a rapid and temporary reversal of membrane potential—an action potential—which is propagated along the neuronal membrane. Notably, the amplitude of the action potential does not vary with the strength of stimulation; instead, once a threshold is reached, a full action potential occurs (the so-called *all-or-none phenomenon*). However, the degree of neuronal stimulation can alter the frequency of action potentials generated. In this way, neurons transmit information to other neurons and effector tissue cells.

Neuronal signals are transferred across neuron-to-neuron connections (synapses) via chemical neurotransmitters. This process begins with bursts of neuronal firing, which result in the opening of voltage-gated calcium channels at the axon terminal. The influx of calcium promotes exocytosis of neurotransmitter-containing synaptic vesicles, releasing neurotransmitters into the synaptic cleft. Neurotransmitters then activate specific ligand-dependent ion channels in the postsynaptic membrane, which can stimulate an action potential in the postsynaptic neuron. A wide variety of factors serve as neurotransmitters, including amino acids (e.g., acetylcholine, glutamate, γ-aminobutyric acid [GABA]), biogenic amines (e.g., norepinephrine, epinephrine, dopamine, serotonin), and neuropeptides (e.g., kisspeptin, neurokinin B [NKB], dynorphin, β-endorphin, somatostatin, proopiomelanocortin [POMC], neuropeptide Y [NPY]).

Bursts of neuronal firing can also elicit release of neuronal products into the bloodstream to influence remote targets (i.e., neurosecretion of neurohormones). Hypophysiotropic neurons are specialized hypothalamic neurons that secrete peptide-releasing factors (GnRH, corticotropin-releasing hormone [CRH], thyrotropin-releasing hormone [TRH], and growth hormone–releasing hormone [GHRH]) into the hypophyseal portal circulation. These releasing factors in turn stimulate specific anterior pituitary cell populations. In contrast, hypothalamic release of dopamine into the portal circulation provides tonic inhibition of pituitary prolactin secretion. Hypothalamic neurosecretion of vasopressin and oxytocin, which are released directly into the systemic circulation, alter the function of distant targets such as the renal tubules and uterus, respectively.

Neuroglial cells (e.g., astrocytes, ependymal cells, oligodendrocytes, microglia) represent approximately 90% of cells in the CNS. Neuroglia do not conduct action potentials, but they perform critical supportive functions. For example, astrocytes form the supportive framework of the CNS, help isolate synaptic junctions to prevent nonspecific spread of neuronal impulses, facilitate nutrient delivery to neurons, and contribute to the blood-brain barrier. Of interest, astrocytes have been implicated in the control of GnRH secretion and the mechanisms underlying pubertal onset.[2] For example, astrocytes may impact neuronal activity via secretion of numerous growth factors, and astrocytes abundantly appose GnRH neurons; these contacts can influence synaptic input and may be influenced by estrogen in both rodents and nonhuman primates. Similarly, specialized ependymal cells (tanycytes) in the median eminence appear to modify access of GnRH neuron terminals to the hypophyseal portal system.

## Anatomy of the Reproductive Hypothalamic-Pituitary Axis

- *GnRH neuronal cell bodies are located in the infundibular (arcuate) nucleus and the medial preoptic area of the hypothalamus.*
- *GnRH neurons extend processes to the median eminence, where GnRH gains access to the hypophyseal portal system.*
- *The hypophyseal portal circulation represents the functional connection between hypothalamic GnRH neurons and the gonadotropes of the anterior pituitary.*

Portions of the hypothalamus and the anterior pituitary gland constitute the primary effector arm of the central reproductive axis. In particular, hypothalamic neural systems regulate GnRH release into the hypophyseal portal veins, with GnRH being the signal to gonadotropes (anterior pituitary) to secrete LH and FSH. In turn, these gonadotropins direct gonadal (ovarian and testicular) function.

### Hypothalamus

The hypothalamus is located at the base of the brain (Fig. 1.2). Although small (approximately 10 g, less than 1% of total brain weight), it performs critical functions for maintenance of whole-organism homeostasis, including regulation of hunger and body weight, growth, various aspects of metabolism, thirst and renal water handling, body temperature, autonomic function, sleep, circadian rhythms, and emotion. Importantly, the hypothalamus is also a primary control center for reproduction and influences sexual behavior.

As an anatomic structure, the hypothalamus does not have discrete borders, but it generally forms the floor and inferior-lateral walls of the third ventricle (Fig. 1.3). The medial portions of the hypothalamus are primarily made up of cell bodies, whereas the lateral portions are mostly composed of neuron fibers (axons), such as those connecting the medial hypothalamus to other areas of the brain. By convention, closely associated collections of neuron cell bodies are called nuclei; and the paraventricular, dorsomedial, ventromedial, and infundibular nuclei contain a majority of the neurons that secrete hypophysiotropic hormones into the portal circulation. (The human infundibular nucleus is the analogue to the arcuate nucleus in lower mammalian species.) GnRH cell bodies do not form discrete nuclei but are instead diffusely located throughout the preoptic area and the mediobasal

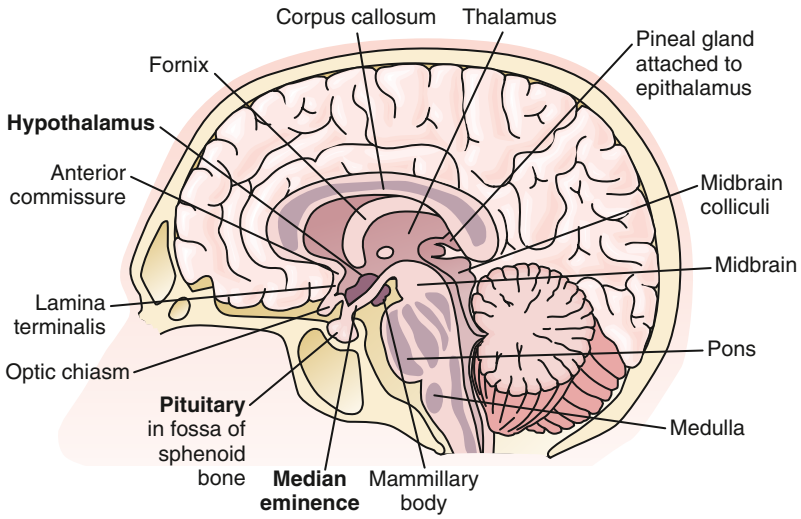


**Fig. 1.2 Cross-sectional representation of the human brain (sagittal plane), including hypothalamus, median eminence, and pituitary gland.** (Modified from Johnson MH, Everitt BJ. *Essential Reproduction,* ed 5, Blackwell Science; 2000:Fig. 6.1.)

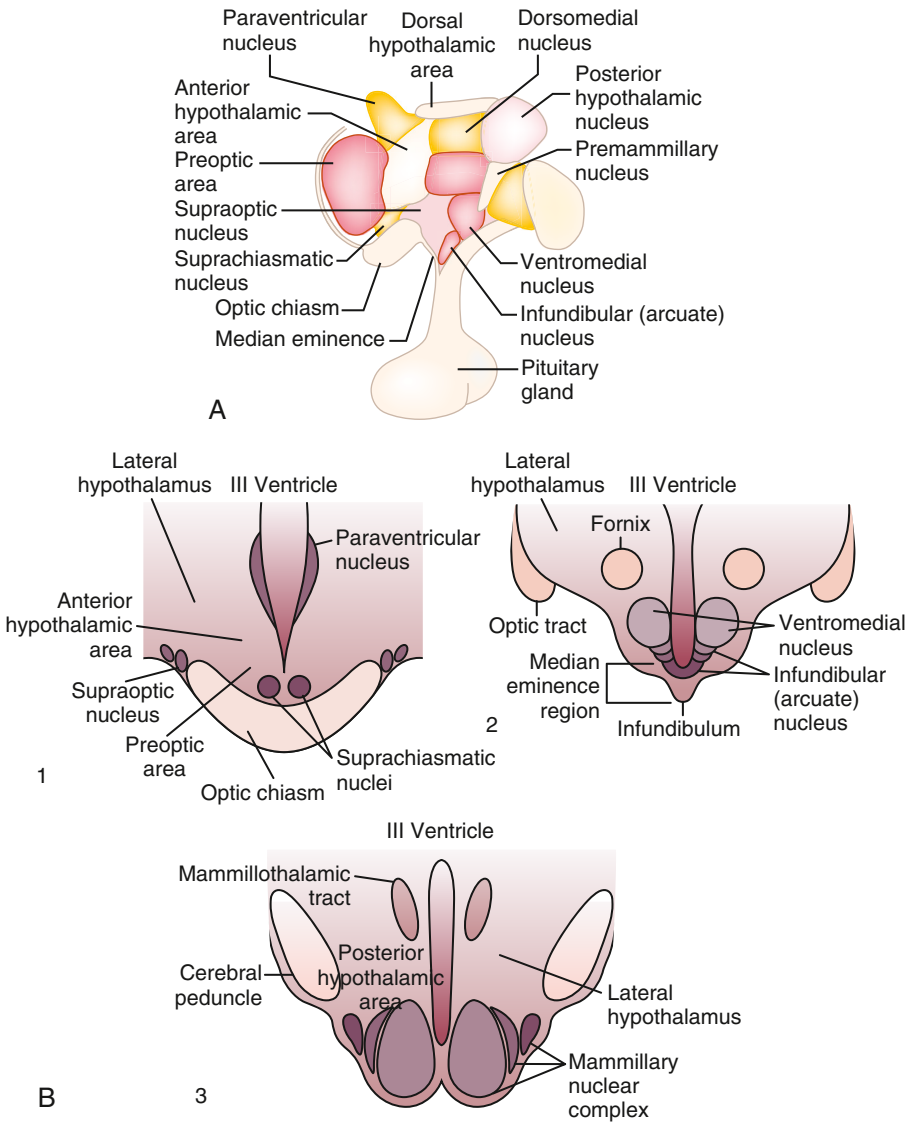


**Fig. 1.3 Nuclei and areas of the hypothalamus. (A)** By custom, the nuclei and areas of the hypothalamus are often divided into three groups according to their location along the anteroposterior plane: the anterior group, the tuberal group, and the posterior (or mammillary) group. The anterior group is formed by the paraventricular, supraoptic, and suprachiasmatic nuclei, along with the anterior hypothalamic and preoptic areas. The tuberal group—so-called because of its position above the tuber cinereum, from which the infundibulum or pituitary stalk extends, contains the dorsomedial, ventromedial, and infundibular (arcuate) nuclei along with the median eminence. Along with the paraventricular nucleus, the nuclei of the tuberal group contain a majority of the neurons that secrete hypophysiotropic hormones (i.e., hypothalamic hormones regulate hormone synthesis and release from cells in the anterior pituitary). Finally, the posterior group includes the posterior hypothalamic nucleus and mammillary nuclei. **(B)** Cross-sectional representations (coronal planes) of the rostral (1), mid (2), and caudal (3) portions of the human hypothalamus. ([B] Modified from Johnson MH, Everitt BJ. *Essential Reproduction*, ed 5, Blackwell Science; 2000:Fig. 6.3.)

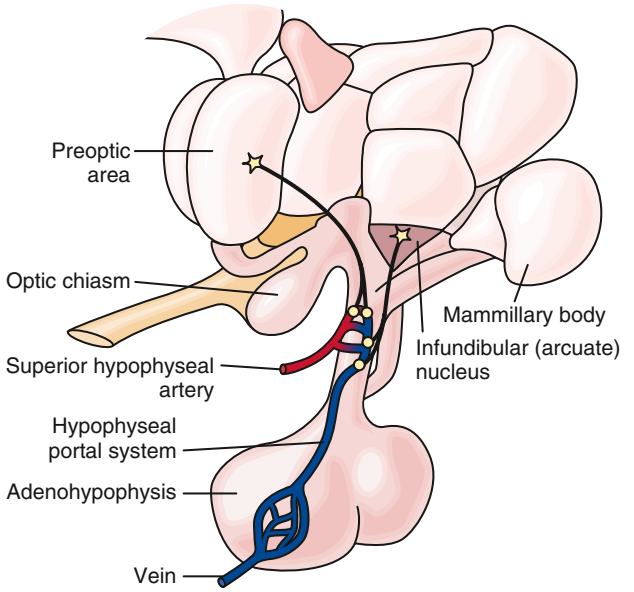


**Fig. 1.4 Anatomic relationship between hypothalamic gonadotropin-releasing hormone *(GnRH)* neurons and their target cell populations in the adenohypophysis (anterior pituitary).** The majority of GnRH neuron cell bodies are located in the infundibular (arcuate) nucleus and the medial preoptic area. GnRH neuron projections terminate at the median eminence, where GnRH is secreted into the hypophyseal portal system. (Modified from Johnson MH, Everitt BJ. *Essential Reproduction*, ed 5. Blackwell Science; 2000:Fig. 6.4.)

hypothalamus (Fig. 1.4); the latter is situated caudal to the preoptic area, extending from the retrochiasmatic area (i.e., the area located behind the optic chiasm) to the mammillary bodies, and including both the infundibular (arcuate) nucleus and the median eminence.

## Median Eminence

Positioned at the base of the third ventricle, the median eminence is part of the anatomic link between the hypothalamus and anterior pituitary. The internal zone of the median eminence is located along the ventral floor of the third ventricle and is largely composed of axonal fibers from both magnocellular neurons (larger neurons that secrete vasopressin and oxytocin) and hypophysiotropic neurons as they travel from hypothalamic nuclei/areas to their final destinations; the neurohypophysis (posterior pituitary) and the external zone of the median eminence, respectively (Fig. 1.5). The external zone contains hypophysiotropic neuron terminals, which release hypophysiotropic hormones into an extensive capillary plexus (the proximal end of the hypophyseal portal system). Some nerve terminals in this zone act on other nerve terminals to influence hormone release (e.g., kisspeptin neurosecretion at GnRH neuron terminals influences GnRH release).

The ependymal layer lining the third ventricle includes a population of specialized ependymal cells called tanycytes, which have a short process extending toward the ventricular surface and a long process extending into the median eminence toward areas around portal capillaries. The latter tanycyte projections envelop or retract from GnRH nerve terminals during episodes of low and high GnRH neuronal activity, respectively. Thus, tanycytes may influence GnRH secretion via the regulated process of physically isolating GnRH neuron terminals from portal capillaries.[3] Tanycytes may also represent a link between cerebrospinal fluid and the external zone of the median eminence (e.g., by transport ing substances from the third ventricle to portal blood).

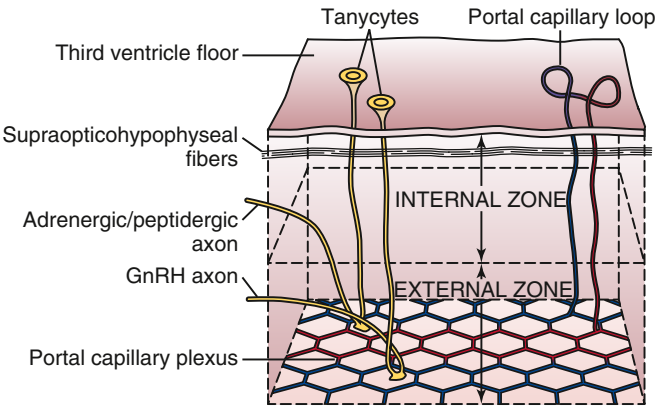


**Fig. 1.5 Diagram of the median eminence.**

The median eminence is among the so-called circumventricular organs, which lie adjacent to the ventricular system and represent openings in the blood-brain barrier. Although lipid-soluble molecules can diffuse in and out of the CNS relatively easily, and cellular transport mechanisms allow selective entry of ions, the blood-brain barrier functions to protect certain regions of the brain and hypothalamus from larger charged molecules, with physical protection provided by (1) tight junctions between endothelial cells and (2) neuron-capillary separation by both astrocyte foot processes and microglia. However, the CNS requires feedback signals, including hormonal, metabolic, and toxic cues via macromolecules of peripheral origin that would otherwise be excluded by the blood-brain barrier. Accordingly, capillaries of the circumventricular organs are fenestrated and permit transcapillary exchange of larger charged molecules (e.g., proteins, peptide hormones). Thus the median eminence represents a key access point for central sensing of peripheral cues. Similarly, fenestrated vessels readily allow entry of hypothalamic-releasing factors into portal blood.

## Hypophyseal Portal Circulation

No direct neuronal connections exist between the hypothalamus and the anterior pituitary. However, the hypophyseal portal circulation (hypothalamic-hypophyseal portal system, pituitary portal system) represents the functional connection between the median eminence and the anterior pituitary (see Fig. 1.4). The superior hypophyseal artery—a branch of the internal carotid artery—subdivides to form an extensive capillary network in the external zone of the median eminence, with loops that reach into the inner zone. Capillary blood then drains into sinusoids that converge into the hypophyseal portal veins. Traversing the pituitary stalk, the hypophyseal portal system forms the primary blood supply of the anterior pituitary. The direction of blood flow is primarily, but not exclusively, from the hypothalamus to the anterior pituitary; some retrograde flow allows for short-loop hypothalamic feedback.

## Pituitary Gland (Hypophysis)

The pituitary gland appears as an extension at the base of the hypothalamus and resides cradled within the sella turcica, a saddle-like structure of the sphenoid bone (see Fig. 1.2). The adenohypophysis (anterior pituitary) is of ectodermal origin, derived from an upward invagination of pharyngeal epithelium (Rathke pouch) during embryologic development. The adenohypophysis is composed of primarily the anterior lobe (pars distalis), which contains specialized cell populations that produce specific hormones: gonadotropes (the gonadotropins LH and FSH), mammotropes (prolactin), corticotropes (adrenocorticotropic

hormone [ACTH]), thyrotropes (thyroid-stimulating hormone [TSH]), and somatotropes (growth hormone). The intermediate lobe is vestigial in adult humans but includes a small population of cells (e.g., POMC cells) in contact with the posterior lobe; the pars tuberalis is a slender layer of tissue (e.g., LH-producing cells and TSH-producing cells) surrounding the infundibulum (the funnel-shaped connection between the hypothalamus and the posterior pituitary) and pituitary stalk.

In contrast to the adenohypophysis, the neurohypophysis (posterior pituitary) is composed of neural tissue and forms as a downward extension of neuroectodermal tissue from the infundibulum during embryologic development. It is thus a direct extension of the hypothalamus. The neurohypophysis includes the infundibular stalk and the pars nervosa (posterior lobe of the pituitary). The supraoptic and paraventricular nuclei include magnocellular neurons that produce oxytocin and arginine vasopressin (AVP; also known as antidiuretic hormone [ADH]), respectively; these axons project to the posterior lobe of the pituitary, where oxytocin and AVP are secreted into a capillary network that drains into the hypophyseal veins (i.e., directly into the systemic circulation). The posterior lobe also includes specialized glial cells called pituicytes, which envelop or retract from magnocellular nerve terminals during episodes of low and high neuronal activity, respectively.

## Gonadotropin-Releasing Hormone: The Final Common Pathway for the Central Control of Reproduction

- *Pulsatile GnRH secretion is the proximate stimulus for LH and FSH synthesis and secretion by pituitary gonadotropes.*
- *Although numerous internal and external factors influence gonadotropin secretion via numerous neuronal pathways, GnRH is the final common pathway for the stimulation of LH and FSH release.*

GnRH, previously called luteinizing hormone–releasing hormone (LHRH), is synthesized and released by a relatively small population of specialized hypothalamic neurons. GnRH was initially isolated from porcine hypothalami and shown to stimulate pituitary gonadotropin release.[4] Although the primary function of GnRH is to regulate pituitary gonadotropin secretion, GnRH also appears to have autocrine and paracrine functions in diverse tissues (e.g., ovary, placenta).[5]

The regulation of GnRH secretion is complex and involves overlapping pathways, which likely increases the robustness of central reproductive function. However, there are no known parallel or backup pathways for the stimulation of gonadotropin secretion. Thus natural fertility is absolutely dependent on appropriate GnRH secretion. For example, mice with loss-of-function variants of the GnRH-1 gene are hypogonadal, but reproduction can be restored via GnRH-1 gene therapy[6] or transplantation of fetal GnRH neurons.[7] Similarly, a variety of human conditions associated with absent (or near-absent) GnRH secretion lead to pubertal failure, hypogonadotropic hypogonadism, and infertility, all of which can be fully reversed with exogenous GnRH therapy.[8]

GnRH secretion is influenced by numerous factors, including sex steroids, energy availability, and stress. In some mammalian species, GnRH secretion is also affected by circadian rhythms, photoperiod (e.g., seasonal breeders such as sheep), social cues, and pheromones.

### Gonadotropin-Releasing Hormone Structure

GnRH (GnRH-1 in particular) is a decapeptide, with the amino acid structure (pyro)Glu-His-Trp-Ser-Tyr-Gly-Leu-Arg-Pro-Gly-$NH_2$. The amino acid structure of GnRH is identical in essentially all mammalian species; with the exception of the central Tyr-Gly-Leu-Arg segment, the amino acids of GnRH are highly conserved among vertebrate species.[9] The GnRH-1 gene *(GNRH1)* is located on human chromosome 8 (8p11.2-p21) and produces a 92–amino acid precursor peptide called prepro-GnRH, which includes a signal sequence (23 amino acids), GnRH (10 amino acids), a proteolytic processing site (3 amino acids), and GnRH-associated peptide (56 amino acids) (Fig. 1.6). The latter peptide can stimulate gonadotropin secretion and inhibit prolactin secretion, although its precise physiologic role, if any, remains unclear. The actions of GnRH are mediated through the GnRH type I receptor.

Another form of GnRH (GnRH-2) and its receptor have been identified in a variety of animal species, including humans.[10] GnRH-2 is a decapeptide with a similar structure to GnRH-1: (pyro)Glu-His-Trp-Ser-*His*-Gly-*Trp*-*Tyr*-Pro-Gly-NH2 (italicized amino acids denote differences compared with GnRH-1). However, the gene for GnRH-2 is located on human chromosome 20 (20p13). GnRH-2 is widely expressed in the CNS and extra-CNS tissues, and it may contribute to reproductive behavior regulation in some species. In lower animals, GnRH-2 can act via its own receptor, which is structurally and functionally distinct from the GnRH type I receptor. Although a homologue of the GnRH-2 receptor gene has

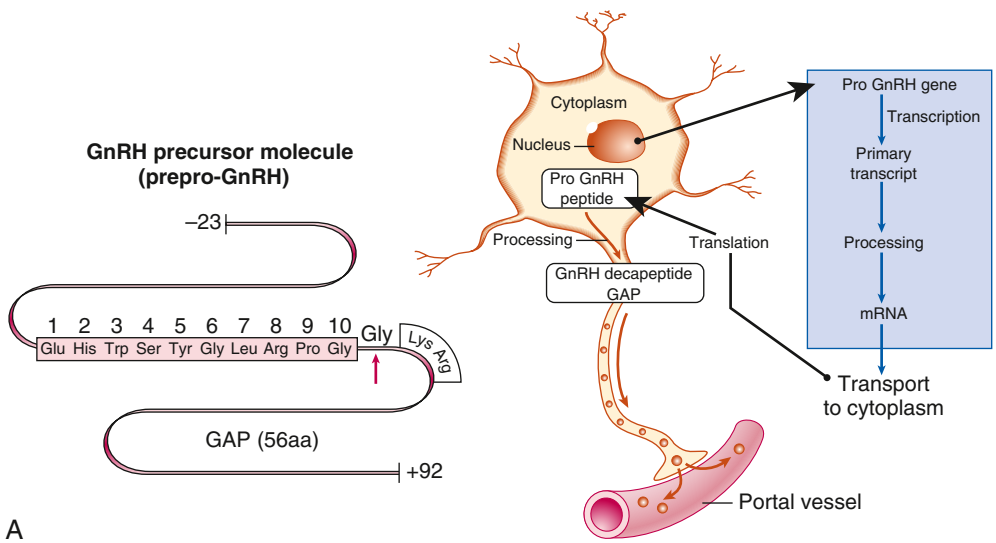


**Fig. 1.6 Schematic of gonadotropin-releasing hormone *(GnRH)* synthesis. (A)** Representation of prepro-GnRH, including a 23–amino acid signal sequence, GnRH, a proteolytic processing site (Gly-Lys-Arg), and GnRH-associated peptide. The *arrow* indicates the site of proteolytic cleavage and C-amidation. **(B)** Schematic of neuronal GnRH synthesis and secretion.

# 3 Prolactin in Human Reproduction

*Nicholas A. Tritos*

## OUTLINE

**INTRODUCTION**
**LACTOTROPH DEVELOPMENT**
**PROLACTIN GENE**
**PROLACTIN SYNTHESIS IN PITUITARY LACTOTROPHS**
**PROLACTIN SYNTHESIS IN THE DECIDUA AND OTHER TISSUES**
**PROLACTIN ASSAYS**
- Hook Effect
- Macroprolactin
- Heterophilic Antibodies
- Exogenous Biotin

**PROLACTIN SECRETION**
- Changes in Prolactin Levels With Age
- Prolactin Levels During Physiologic Stress
- Prolactin Levels During the Menstrual Cycle, Pregnancy, and the Postpartum State

**REGULATION OF SYSTEMIC PROLACTIN LEVELS**
- Prolactin Inhibitory Factors
- Prolactin-Releasing Factors

**PROLACTIN ACTIONS**
- Prolactin Receptor
- Prolactin Effects on the Breast
- Prolactin Effects on Gonadotropin Secretion
- Prolactin Effects on the Ovary
- Prolactin Effects on the Testis
- Prolactin Effects on the Adrenal Cortex
- Prolactin and the Skeleton

**PATHOLOGICAL STATES OF PROLACTIN DEFICIENCY AND EXCESS**
- Prolactin Deficiency
- Hyperprolactinemia: Causes
- Hyperprolactinemia: Diagnosis

**PROLACTIN-SECRETING PITUITARY ADENOMAS (PROLACTINOMAS)**
- Epidemiology and Natural History
- Pathogenesis
- Pathology
- Clinical Manifestations
- Management

**PREGNANCY AND PROLACTINOMAS**
- Prolactin-Secreting Pituitary Adenomas During Preconception and Pregnancy
- Effects of Dopamine Agonists During Preconception and Pregnancy
- Management of Patients With Prolactinomas During Preconception and Pregnancy

## INTRODUCTION

Prolactin (PRL) is a single chain (23 KDa) polypeptide hormone, which is secreted by anterior pituitary lactotroph cells.[1] Several lines of evidence indicate that PRL has an essential role in reproduction and lactation.[2] In addition, animal data have supported a role for PRL in a variety of metabolic processes.[2] However, such PRL actions have not been unequivocally confirmed in humans.[3] The present chapter reviews PRL physiology, followed by a discussion of the role of PRL in pathologic states, including hyperprolactinemia and PRL deficiency. Data on the epidemiology, pathology, clinical evaluation, and management of PRL-secreting pituitary adenomas (prolactinomas) are then reviewed, including data relevant to prolactinomas in the setting of preconception and pregnancy.

## LACTOTROPH DEVELOPMENT

- *Lactotroph cells develop under carefully orchestrated control by several transcription factors.*
- *Lactotroph hyperplasia is physiologic during pregnancy and is reversible postpartum.*

Pituitary lactotrophs are relatively abundant in the human anterior pituitary gland, accounting for up to 25% of cells in individuals of both genders.[4] During embryogenesis, the pituitary gland develops from ectodermal primordial cells destined to form the anterior and intermediate lobe and neuroectodermal tissue arising from the floor of the diencephalon, which ultimately forms the posterior lobe. During development, inductive interactions and a host of transcription factors have a critical role in the formation of the pituitary and differentiation into mature functioning cells.[5–7] Transcription factors and signaling molecules that have been implicated in pituitary ontogenesis include those involved in the initiation of pituitary formation (SIX1, SIX6, HESX1, OTX2, PITX1, PITX2, PITX3, ISL1, LHX3, LHX4, SOX2, beta catenin, NOTCH1, NOTCH2), those involved in the migration and proliferation of cells forming the Rathke's pouch (BMP2, BMP4, FGF8, FGF10, FGF18, SHH) and those involved in lactotroph differentiation (PROP1, POU1F1, GATA2, LHX3).[5–8]

Lactotroph and somatotroph cells generally develop from common progenitor cells (mammosomatotrophs) under the influence of several transcription factors, though it is possible that some lactotrophs may develop through other precursor cell lines.[9,10] In particular, the transcription factor POU1F1 (also known as PIT1), a member of the POU homeodomain transcription factor family, is critical in the differentiation and proliferation of lactotrophs, somatotrophs and thyrotrophs and the expression of genes encoding PRL, growth hormone (GH) and the beta subunit of thyrotropin (TSH beta).[7,9] Patients with inactivating mutations in the *POU1F1* gene lack lactotrophs, somatotrophs, and thyrotrophs, resulting in PRL, GH, and thyrotropin deficiency, respectively. In addi-

PIT1 antibody syndrome develop

PRL, GH, and thyrotropin deficiency as a consequence of autoimmune damage to the respective pituitary cell populations.[11] Another homeodomain transcription factor, known as prophet of PIT1 (PROP1), has a critical role in the expression of POU1F1.[7,9] Patients with inactivating mutations in the *PROP1* gene may have PRL, GH, thyrotropin deficiency as well as gonadotropin (follicle stimulating hormone [FSH] and luteinizing hormone [LH]) deficiency. Patients with inactivating mutations in genes encoding other transcription factors, including HESX1, LHX3, and LHX4, generally have multiple pituitary hormone deficiencies as well as other midline cranial defects.[7,9]

## PROLACTIN GENE

- *A single gene encodes prolactin in humans.*
- *Prolactin gene transcription is increased by estradiol and inhibited by thyroid hormone.*
- *Dopamine, the major factor regulating prolactin secretion in humans, acts by inhibiting adenyl cyclase–dependent signaling pathways.*

In humans, the gene encoding PRL consists of 5 coding exons, one noncoding exon, and four introns. It spans approximately 10 Kb in length and is located on chromosome 6.[12,13] There are several regulatory elements located in the 5' region of the *PRL* gene, including areas responsible for stimulation of *PRL* gene transcription in response to POU1F1 or estradiol, as well as those responsible for suppression of *PRL* gene transcription by thyroid hormone.[14–18] In addition to its direct effects, estradiol also modulates dopamine (DA)-induced inhibition on *PRL* gene transcription.[19–21] The stimulatory effects of POU1F1 on *PRL* gene transcription are also subject to modulation by a variety of factors, including cyclic adenosine monophosphate (cAMP), glucocorticoids, estradiol, thyrotropin-releasing hormone (TRH) and epidermal growth factor (EGF).[14–16,22–24]

Dopamine is the major inhibitory factor regulating PRL secretion and acts through the D2 dopamine receptor to inhibit adenyl cyclase and the cAMP-dependent protein kinase A (PKA) pathway.[25] In contrast, TRH stimulates PRL secretion via the phosphoinositide pathway, leading to the activation of membrane calcium channels and the release of calcium ions from the endoplasmic reticulum into the cytoplasm, which in turn activate protein kinase C (PKC), causing the downstream phosphorylation of other proteins, and also bind to calmodulin or topoisomerase II, which have a variety of downstream actions.[26] Of note, dopamine inhibits PRL secretion caused by intracellular calcium ion release.[27] This dopamine action is antagonized by several calcium channel antagonists in vitro, including verapamil, diltiazem, and nimodipine.[28] Interestingly, verapamil causes the opposite effect from what would be predicted by in vitro data; that is, it leads to an increase in PRL levels in humans.[29,30] This observation was associated with decreased tuberoinfundibular dopamine release and may involve an effect of verapamil on N-type calcium channels present in neurons.[31] Other types of calcium channel antagonists, including dihydropyridines and benzothiazepines, do not affect PRL levels in vivo.[31]

Vasoactive intestinal peptide (VIP) stimulates adenyl cyclase, leading to PRL secretion.[32] Several factors that stimulate PRL secretion, including TRH, neurotensin, and angiotensin II, may also act via the stimulation of phospholipase A2, leading to the release of arachidonic acid, which causes an increase in calcium influx.[33–35] This effect can be antagonized by dopamine and phospholipase A2 inhibitors.[33,36]

## PROLACTIN SYNTHESIS IN PITUITARY LACTOTROPHS

- *Several posttranslational prolactin modifications occur and influence prolactin bioactivity.*
- *Macroprolactin species are large prolactin aggregates that have decreased bioactivity.*
- *A 16 kDa prolactin fragment has been implicated in the pathogenesis of peripartum cardiomyopathy and preeclampsia.*

The *PRL* gene is transcribed to mRNA, which undergoes processing in the nucleus to yield a mature, 1 Kb mRNA species, encoding a 227 amino acid PRL precursor. This contains a 28 amino acid signal peptide sequence, which is cleaved posttranslationally to yield a 199 amino acid PRL protein.[1,13] Additional posttranslational modifications of the PRL molecule include glycosylation, phosphorylation, cleavage, and polymerization.

Of note, the large majority (80%–90%) of the circulating PRL is monomeric, whereas about 10% of circulating PRL is dimeric ("big PRL," molecular mass ~50 KDa) and approximately 5% of circulating PRL is multimeric ("big big PRL").[37–39] Such high molecular mass PRL species are collectively called "macroprolactin" and may additionally contain bound immunoglobulin.[40] Macroprolactin has been reported to exhibit decreased binding to PRL receptors and has lower receptor binding affinity and decreased bioactivity in most, but not all, assays.[38,39] Patients with macroprolactinemia, who have elevated total serum PRL as a consequence of elevated multimeric PRL, appear to have normal pituitary-gonadal function, likely as a consequence of decreased bioactivity of multimeric PRL species.[39,41–43]

Cleavage of the 23 KDa PRL species by metalloproteases or cathepsin D may occur in peripheral tissues, leading to the generation of an N-terminal 16 KDa PRL variant.[44] This PRL species has antiangiogenic, proapoptotic, and proinflammatory properties and has been implicated in the pathogenesis of peripartum cardiomyopathy and preeclampsia, based on animal and human data.[44–48] Bromocriptine therapy decreases serum PRL and improves cardiac function in women with peripartum cardiomyopathy.[49–51]

## PROLACTIN SYNTHESIS IN THE DECIDUA AND OTHER TISSUES

- *Extrapituitary prolactin secretion occurs in the decidua and other tissues.*
- *Prolactin of decidual origin appears to promote immunological tolerance of the fetus in utero.*
- *The physiologic role of extrapituitary prolactin in other tissues remains incompletely understood in humans.*

Several lines of evidence suggest that PRL is synthesized in the decidua.[52,53] Very high PRL levels (10–100 times those in maternal serum) have been found in amniotic fluid.[52,53] In culture, decidual and chorion cells secrete PRL.[54] This PRL species is identical in sequence and activity to pituitary PRL and is expressed under control by an alternative promoter, which is located upstream from the transcription initiation site used in pituitary lactotrophs.[55,56] Of note, PRL secretion in the decidua is stimulated by progesterone (either alone or together with estrogen), relaxin, insulin, and insulin-like growth factor I (IGF-I) but is not influenced by dopamine agonists or antagonists (in contrast to pituitary PRL).[57–60] Decidual PRL appears to have an important role in maintaining pregnancy by downregulating interleukin 6 and 20 alpha hydroxysteroid dehydrogenase.[61] Of note, decidual PRL synthesis was reduced in decidual tissue from women who had suffered a miscarriage,

# 5 Steroid Hormone Action

*Shannon Whirledge and John A. Cidlowski*

## OUTLINE

**STEROID HORMONE RECEPTORS ACT AS LIGAND-DEPENDENT TRANSCRIPTION ACTIVATORS OR REPRESSORS**

**STEROID HORMONE RECEPTOR STRUCTURE AND THE EVOLUTION OF SPECIFICITY**

**STEROID HORMONE RECEPTOR FUNCTION**
- Estrogen Receptor
- Progesterone Receptor
- Androgen Receptor
- Glucocorticoid Receptor
- Mineralocorticoid Receptor

**GENERAL FACTORS THAT INFLUENCE STEROID HORMONE ACTION**
- Hormone Bioavailability
- Receptor Expression
- Ligand-Bound Changes to Receptor Conformation
- Posttranslational Modifications of the Steroid Hormone Receptors
- Interaction With DNA
- Interaction With Coactivators and Corepressors
- Interaction With Other Transcription Factors
- Nongenomic Actions of Steroids
- Signaling via Second Messenger Cascades

**SUMMARY**

## STEROID HORMONE RECEPTORS ACT AS LIGAND-DEPENDENT TRANSCRIPTION ACTIVATORS OR REPRESSORS

- *Steroid hormones are derived from the metabolic conversion of cholesterol into biologically active steroid products that bind to intracellular receptors with high specificity.*
- *The canonical mechanism of action for the steroid hormone receptors involves regulating gene transcription through transactivation and transrepression.*
- *Precise regulation of gene transcription is essential for development, physiology, and homeostasis.*

Steroids are small, lipophilic hormones synthesized from a common precursor molecule, cholesterol, through a complex biosynthetic process in specific tissues and glands throughout the body (see Chapter 4). Despite their shared molecular origin and basic structural similarities, the steroids *mineralocorticoids*, *glucocorticoids*, *estrogens*, *progestins*, and *androgens* are distinct classes of hormones that interact with specific, high-affinity receptors to exert their unique biological effects (mineralocorticoid [MR], glucocorticoid [GR], estrogen [ER], progestin [PR], and androgen [AR]). These hormones control diverse physiological and cellular processes and affect almost all aspects of eukaryotic physiology, from sexual differentiation, growth, and reproductive functions to immunity, metabolism, behavior, and learning.[1] Consequently, a clear and complete understanding of the general mechanisms of steroid hormone action, as well as those activities that occur in a tissue- and cell-type-specific manner, is of critical importance for the promotion of health and the understanding of disease processes.

This chapter reviews the structural similarities and differences among the steroid hormone receptors, as well as what is known regarding their mechanisms of action. The classic mode of action entails simple diffusion of steroid hormones into the cell, where they interact with cognate receptors and stimulate or inhibit transcription of target genes (Fig. 5.1).[2] The hormone-dependent changes in receptor conformation can drive both the transactivation and transrepression of gene expression by (1) altering interactions with molecular chaperones that keep the receptor in a ligand-independent state; (2) inducing posttranslational modifications that alter receptor activity; (3) promoting the formation of receptor dimers; (4) enhancing interactions with specific DNA sequences (*hormone response elements*); and (5) facilitating recruitment of coactivator or corepressor proteins that alter chromatin structure and contact with the basal transcription machinery.[3] Recent mechanistic studies have built on the classic mode of action to reveal a complex regulatory network of interacting factors and chromatin state.[4,5] For example, steroid hormone receptors have been shown to interact with closed chromatin through the recognition of partial DNA sequence motifs to enable other transcription factors to engage chromatin and form regulatory complexes (e.g., pioneer factors) or work through receptor cooperation to initiate the opening of chromatin and allow for the binding of other steroid hormone receptors or secondary transcription factors.[6,7] In addition to reviewing the various mechanisms of steroid hormone action, this chapter will discuss factors that regulate hormone activity, as well as nonclassical modes of action for steroid hormones and their receptors.

## STEROID HORMONE RECEPTOR STRUCTURE AND THE EVOLUTION OF SPECIFICITY

- *The steroid hormone receptors belong to a large family of transcription factors called nuclear receptors.*
- *The structure of the steroid hormone receptors is modular, with distinct domains. The steroid hormone receptors contain a highly conserved DNA-binding domain (DBD), a moderately conserved ligand-binding domain (LBD), and less well-conserved amino- and carboxy-terminal domains.*
- *Phylogenetic analysis determined that the steroid hormone receptors cluster separately from other ligand-dependent transcription factors. The evolution of the steroid hormone receptors is controversial and may reflect gene duplication, mutation, and functional divergence.*

The steroid hormone receptors belong to a larger family of structurally and evolutionarily related proteins called *nuclear receptors*, encoded by 48 genes in the human genome.[8–10] All nuclear receptors, including the steroid hormone receptors, exhibit a modular structure composed of distinct domains (Fig. 5.2).

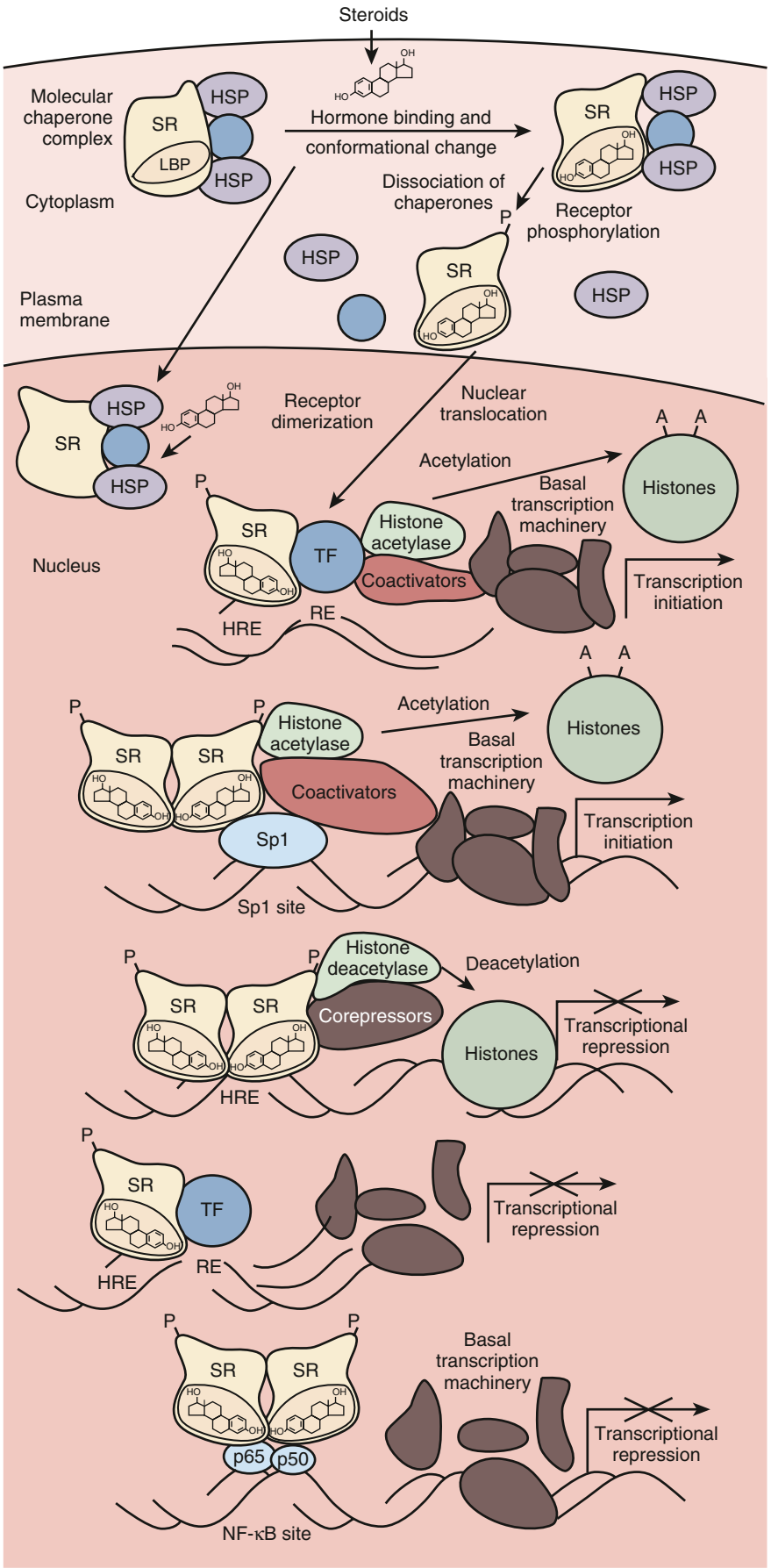


**Fig. 5.1 General mechanism of action for cytoplasmic steroid receptors as described in the text.** The two subunits of nuclear factor kappa B are p50 and p65. *A,* Acetyl group; *HRE,* hormone response element; *HSP,* heat shock protein; *LBP,* ligand-binding pocket; *NF,* nuclear factor; *P,* phosphate group; *SR,* steroid receptor.

# 33 Pelvic Imaging in Reproductive Endocrinology

*Misty Marie Blanchette Porter and Steven Robert Goldstein*

## OUTLINE

**ULTRASOUND EXAMINATION TECHNIQUE**
- Evaluation of the Uterus
- Evaluation of the Endometrium
- Unenhanced Ultrasound of the Uterine Cavity
- Sonohysterography or Saline Infusion Sonography: Enhanced Ultrasound of the Uterine Cavity

**PALM-COEIN**
- Polyp (AUB-P)
- Adenomyosis (AUB-A)
- Three-Dimensional Transvaginal Sonographic Features of Adenomyosis
- Acute Abnormal Uterine Bleeding

**POSTMENOPAUSAL BLEEDING**

**MÜLLERIAN ANOMALIES**
- Imaging Characteristics of Müllerian Anomalies
- Combined Bicornuate/Septate Configuration of the Uterus

**OVARIAN ASSESSMENT**
- Ovarian Reserve
- Polycystic Ovary Morphology
- Automated Follicular Monitoring

**ASSESSMENT OF FALLOPIAN TUBE PATENCY**

**EVALUATION OF DEEPLY INVASIVE ENDOMETRIOSIS**
- Endometrioma(s)
- Compartmental Evaluation

**EARLY PREGNANCY**
- Pregnancy of Unknown Location
- Ectopic Pregnancy
- Diagnosis of Miscarriage

**CONCLUSION**

Ultrasound investigation for subfertility, PALM-COEIN, müllerian anomalies, deeply invasive endometriosis, miscarriage, pregnancy of unknown location

A single-visit ultrasound-based approach in the investigation of subfertility has gained widespread acceptance (Table 33.1).[1] Two-dimensional (2D) ultrasound is the primary tool for the initial investigation of the pelvis and provides a diagnostically accurate, minimally invasive, and cost-effective assessment tool. Technological improvements in high-resolution transvaginal probes, and the use of color Doppler imaging, have allowed for the meticulous assessment of detail within these anatomic structures—called sonomicroscopy[2]—and not only enhanced diagnostic capabilities but elucidated critical data into the *functional status* of these organs (e.g., assessment of ovarian reserve [OR] with an antral follicle count [AFC], or studying the ovarian morphology of the patient with suspected polycystic ovary syndrome [PCOS]). Three- and four-dimensional (3D/4D) volume ultrasound imaging can provide images of the pelvis comparable in quality and orientation to those of magnetic resonance imaging (MRI) and computed tomography (CT), but without radiation and at a relatively lower cost.[3] The relative ease and efficiency of the acquisition of 3D volume ultrasound sets allow for the storage of entire volumes of imaging. This enables the offline examination and manipulation of additional images obtained within the volume set, with the possibility of creating hundreds of new images, and perhaps future consultation with expert sonographers. Further, the dynamic nature of ultrasound imaging of the pelvis has the added advantage of enhancing a detailed physical exam, allowing for the additional inquiry of sites that might elicit the patient's symptoms such as pain, and detect the presence of adhesions, and thus correlate those symptoms with specific anatomic findings.

**TABLE 33.1** The "Pivotal," Single-Visit, Ultrasound Assessment in Infertility

| |
|---|
| High-resolution transvaginal ultrasound approach preferred |
| Proliferative phase (~CD 4–9) |
| **Uterus and Uterine Cavity** |
| Dimensions/neoplasms |
| 3D coronal view |
| "Sliding" organs sign |
| **Endometrium** |
| Appearance/thickness |
| Sonohysterography/enhanced contrast ultrasound |
| **Ovarian** |
| Morphology: normal/polycystic |
| Position/mobility |
| Volume |
| Antral follicle count |
| Ovarian masses |
| **Tubal Patency** |
| Tubal morphology |
| Hystero-contrast-sonography (HyCoSy) |
| **Cul-de-sac** |
| Presence or absence of free fluid/masses within pelvis |
| Rectoseptal endometriosis/adhesions |

Modified from Kelly SM, Sladkevicius P, Campbell S, Nargund G: Investigation of the infertile couple: a one-stop ultrasound-based approach. *Hum Reprod*. 2001;16(12):2481–2484.

## ULTRASOUND EXAMINATION TECHNIQUE

- *A dynamic ultrasound exam of the pelvis allows for a detailed assessment of pelvic anatomy in addition to elucidating potential sources of pelvic pain and adhesions.*
- *Measurement of the uterus and ovaries may be important diagnostic tools in the evaluation of the pubertal patient with an endocrinopathy.*
- *Sonohysterography (SHG), or saline infusion sonography, is highly likely to aid in the detection of intracavitary pathology.*

In most women, a transvaginal sonographic (TVS) approach in the early proliferative phase of the menstrual cycle (~cycle day 4 to 9), when the patient is not actively bleeding and prior to ovulation, is preferred. A transabdominal scan (TAS) may be required for imaging of pelvic structures beyond the focal length of the probe, and/or out of the pelvis, such as in the case of an enlarged myomatous uterus, a uterus adherent to the anterior abdominal

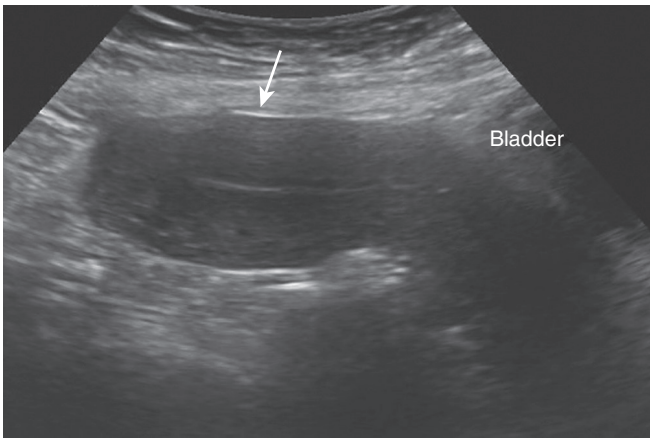


**Fig. 33.1 A transvaginal approach to assessment of the uterus and adnexa is preferred, yet a transabdominal scan may be required for imaging of pelvic structures beyond the focal length of the probe, and/or out of the pelvis, such as in the case of this uterus adherent to the anterior abdominal wall secondary to prior uterine surgery.** Indications the uterus may be adherent out of the pelvis include the fundal apex noted beyond the focal range of the vaginal probe, a "flattened" uterine anterior contour *(arrow)*, the absence of small bowel within the anterior cul-de-sac, a bladder that fills but does not expand over the anterior surface of the uterus, and absence of an anterior "sliding" sign on a dynamic bimanual ultrasonographic exam.

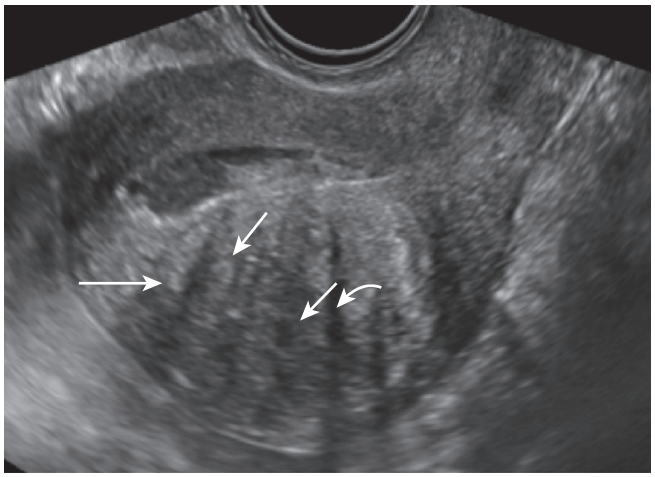

**Fig. 33.2 Longitudinal view of the uterus demonstrating asymmetry between the anterior and posterior uterine walls, a single, well-defined posterior uterine wall mass consistent in appearance with an adenomyoma *(long narrow arrow)*.** The mass demonstrates hypoechoic *(bent arrow)* and hyperechoic cystic change *(short arrow)* and "fan-shaped" shadowing.

wall (Fig. 33.1), or an ovary adherent out of the pelvis. When a TVS is considered inappropriate (e.g., patients who are virginal, vaginismus, or secondary to vaginal stenosis), or if the TAS is inconclusive, a transrectal ultrasound exam should be considered. The bladder is often emptied prior to the initiation of a TVS, but it may be necessary to fill the bladder a small amount to displace the small bowel from the field of view to enhance the quality of the imaging. Image quality during TAS may be hampered by adiposity, scar tissue, bowel gas, or an axial uterine position.

Examination by TVS commences with a dynamic 2D scan of the vagina, bladder, and cervix. The position of the uterus is noted and measurements are taken. An entire overview of the uterus is obtained with the scanned proceeding in the sagittal plane from cornu to cornu, and in the (oblique) transverse plane from cervix to fundus. The uterine corpus view is then magnified as large as possible, focusing on the area of interest. Gentle pressure applied by the examiner's free hand on the abdomen and simultaneously applied to the vaginal probe may be used dynamically to assess uterine, cervical, and ovarian mobility, and their possible pathologies relative to the static pelvic wall, and/or adherence to the large and small bowel. Difficulties in imaging of the detail of the uterine anatomy may arise from variations of the uterine position (particularly when axial), or with uterine rotation secondary to adhesions. This dynamic exam allows for the identification of the possible presence of adhesions, such as uterine fundal attachment to the anterior abdominal wall, or adhesions of the uterus to the colon such as in cul-de-sac obliteration in endometriosis. The dynamic ultrasound-guided exam may also serve to pinpoint the potential causes of pain and screen for site-specific tenderness.[4]

Ultrasonographic measurements of pelvic organs show a high level of agreement with those measured with geometric calipers shortly after surgical excision.[5] In 28 women planning total abdominal hysterectomy, Saxton et al. compared transabdominal ultrasound (TAU) pelvic organ measurements obtained in the perioperative period to absolute dimensions of the excised pelvic organs and found no significant difference between the two methods for uterine cross-sectional area ($r$ = –0.26), endometrial thickness (EMT; $r$ = 0.29 mm), and right ovary ($r$ = 0.14).[5] Measurements for the left ovary were significantly different when the left ovary was larger (> 10 cm$^3$; $r$ = 0.55), a finding attributed to the potential confounders of measuring the left ovarian measurement on TAU (bowel gas and distortion by adjacent sigmoid colon anatomy).[5] Further evidence to support the ability of ultrasound to mirror clinical data includes a nearly perfect correlation between the number of follicles observed at ultrasound (US) and the histologic number documented in the polycystic ovary (PCO) morphology and the degree of ovarian stromal hyperplasia (a marker for androgen excess).[5]

## Evaluation of the Uterus

In clinical practice the uterine corpus is measured in three dimensions, the symmetry of the myometrial walls is estimated, and the overall echogenicity of the myometrium is reported as homogeneous or heterogeneous (Table e33.1) (see Chapter 26).[6] If a myometrial lesion is observed, it is described as well-defined or ill-defined, the number (or an estimated number if there are more than four lesions) is reported, as well as the location and maximal diameter of the clinically relevant lesion(s) (Fig. 33.2).[6] The presence of shadowing, myometrial cysts, hyperechogenic islands, and/or subendometrial echogenic lines and buds is reported and is indicative of the presence of adenomyosis. The anterior and posterior myometrial walls are measured from the external uterine serosa to the external endometrial contour and should include the junctional zone (JZ) but exclude the endometrium. The total length of the cervical canal is measured after identifying the external os of the cervix. The two primary constituents of the uterus—the myometrium and the endometrium—are present at an interface that is easily identifiable on ultrasound. The lower end of the endometrium delineates the internal os of the cervix, which provides the landmark for individual measurements of the cervix and the uterine corpus.

The JZ (also referred to as the inner myometrium, archimyometrium, or stratum subvasculare) is visible as a hypoechogenic subendometrial halo and is of müllerian origin (Fig. 33.3). It lies between the echogenic basal layer of the endometrium and the underlying myometrium. The JZ is confirmed as a distinct structure not only because of its embryonic origin but also in terms of its specialized functions. The JZ is composed of longitudinal and circular closely packed smooth-muscle fibers that are endowed with estrogen receptors (ER) and progesterone receptors (PR) and exhibit a cyclical pattern that parallels that of the endome-

A systematic morphometric and immunohistochemical

**ETABLE 33.1** Reporting the Myometrium in General Clinical Practice

| Feature to Be Described | Description/Term |
|---|---|
| Uterine corpus | Length, anteroposterior diameter, transverse diameter (cm) |
| Myometrial walls | Symmetrical/asymmetrical |
| Overall echogenicity | Homogeneous/heterogeneous |
| Myometrial lesions | Well-defined/ill-defined |
| Number | Number (1, 2, 3, or estimated in case of > 4 lesions) |
| Location | Location of the largest/clinically relevant lesion(s): anterior, posterior, fundal, right lateral or left lateral, global |
| Site | Site (for well-defined lesions) of the largest/clinically relevant lesion(s): FIGO classification 1–7 |
| Size | Maximum diameter of the largest/clinically relevant lesion(s) |
| Shadowing | — |
| Edge shadows | Present/absent |
| Internal shadows | Present/absent |
| Fan-shaped shaped shadowing | Present/absent |
| Cysts | Present/absent |
| Hyperechogenic islands | Present/absent |
| Subendometrial echogenic lines and buds | Present/absent |
| Junctional zone | Regular/poorly defined |
| Vascularity of myometrium | — |
| Overall vessel pattern (in the whole uterus) | Uniform/nonuniform |
| Amount of color (in a lesion): color score | (1) No color, (2) minimal color, (3) moderate color, (4) abundant color |

*FIGO*, International Federation of Gynecology and Obstetrics.

Modified from Van den Bosch T, Dueholm M, Leone FP, et al. Terms, definitions and measurements to describe sonographic features of myometrium and uterine masses: a consensus opinion from the Morphological Uterus Sonographic Assessment (MUSA) group. *Ultrasound Obstet Gynecol*. 2015;46(3):284–298; and Munro MG, Critchley HO, Broder MS, Fraser IS; FIGO Working Group on Menstrual Disorders. FIGO classification system (PALM-COEIN) for causes of abnormal uterine bleeding in nongravid women of reproductive age. *Int J Gynaecol Obstet*. 2011;113(1):3–13.

**TABLE 33.4** Two-Dimensional Transvaginal Sonographic Features of Adenomyosis

| |
|---|
| Globally enlarged uterus: the fundus of the uterus appears to be enlarged |
| Asymmetrically enlarged uterus: anterior wall thicker than the posterior wall, unrelated to myomas |
| Myometrial cysts: rounded cystic area within the myometrium with power Doppler used to distinguish myometrial cysts from blood vessels |
| Inhomogeneous and irregular myometrial echotexture in an indistinctly defined myometrial area with decreased or increased echogenicity; hyperechogenic islands, subendometrial lines, and buds |
| "Fan-shaped shadowing": myometrial hypoechoic linear striations seen as a radiating pattern of thin acoustic shadows not arising from echogenic foci or leiomyomas |
| Indistinct, fuzzy endometrial-myometrial border (ill-defined endometrial stripe) |
| Presence of diffuse minimal vascularity seen as diffuse spread of small vessels without the normal course of the arcuate or radial arteries inside the myometrium |
| "Question Mark Sign": corpus flexed backward, the fundus of the uterus faces the posterior pelvic compartment, and the cervix is directed frontally toward the uterine bladder |

From Di Donato N, Bertoldo V, Montana G, et al. Question mark form of uterus: a simple sonographic sign associated with the presence of adenomyosis. *Ultrasound Obstet Gynecol*. 2015;46(1):126–127.

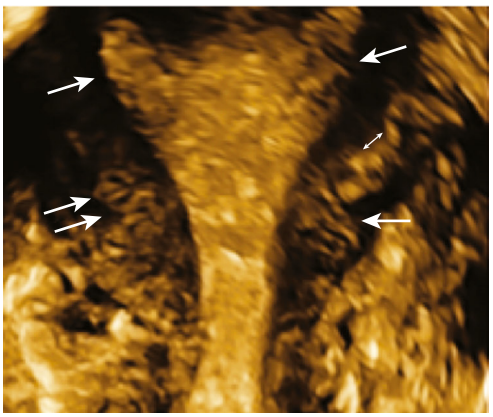

**Fig. 33.16 Three-dimensional coronal view of a patient with adenomyosis.** Note the "halo" of the junctional zone *(JZ)* is indistinct with distortion and infiltration of hyperechoic endometrial tissue into the JZ. The JZ is irregular and interrupted *(single arrows)* within this image with hyperechoic buds *(double arrows)* and line *(thick arrow)*, and cystic areas *(double-headed arrow)*.

not visible, not assessable, or may manifest with more than one feature. Any irregularity in the JZ (e.g., hyperechoic buds and lines, cystic areas) and their location within the uterus should be described (Fig. 33.16).

In addition to the subjective morphologic evaluation of the JZ, objective parameters such as thickness of the JZ (representative of the severity of adenomyosis), similar to those reported in MRI imaging, have been proposed.[94] A maximal thickness of the JZ (JZmax) is measured in the area where the JZ appears to be the thickest, and the minimal thickness (JZmin) is measured at the thinnest portion. A total myometrial thickness is measured perpendicular to the endometrium on the same section. The *magnitude* of the JZ irregularity, and thus the severity of the adenomyosis, is expressed as the difference between the maximal and minimal JZ thickness: JZmax – JZmin = JZdiff (Fig. 33.17). The *extent* of the JZ irregularity can be reported as the subjective estimation of the percentage of the JZ that is irregular (< 50% or ≥ 50%). It has been observed that pelvic endometriosis, especially in advanced stages, is strongly associated with JZ thickening and adenomyosis.[94]

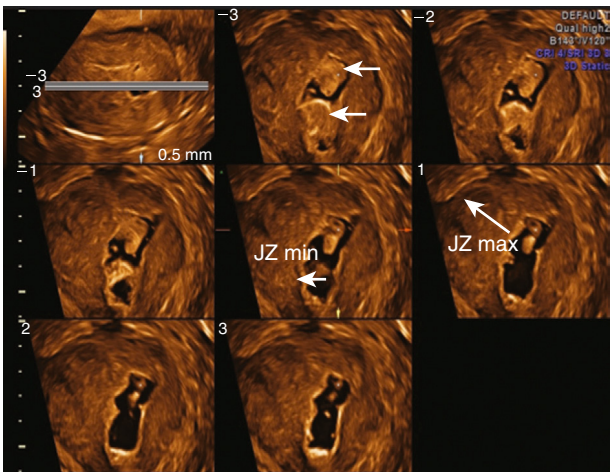


**Fig. 33.17 Three-dimensional tomographic ultrasound imaging of a sonohysterography performed for abnormal uterine bleeding.** The presence of a focal area of adenomyosis *(circle)* in the right cornua and the presence of hyperechoic intracavitary endometrial polyps *(thick arrows)*. The *magnitude* of the junctional zone *(JZ)* irregularity can be expressed as the difference between the maximal and minimal JZ thickness: JZmax – JZmin = JZdiff, and the extent of the adenomyosis estimated.

## Leiomyoma (AUB-L)

On ultrasound, uterine fibroids appear as solid, well-defined round lesions within the uterine corpus, and rarely within the cervix. The myomas often have an inhomogeneous echo-architecture, may be hypo- or hyperechoic, and are characterized by variable degrees of acoustic shadowing and refractive artifacts (Fig. 33.18A and B). The echogenicity of the lesion varies with cellular content of muscle, fibrous stroma, calcification, and the degree of cystic, lipomatous, hemorrhagic, or hyaline degeneration. Myomas associated with fatty degeneration (see Fig. 33.18C), and those with dense calcium deposits, appear hyperechoic. Myomas typically demonstrate diffuse but mostly peripheral flow on color or power Doppler (Fig. 33.19). Both TAS and TVS may be needed to adequately evaluate the uterus; large or pedunculated myomas may be missed by TVS alone. A pedunculated myoma may be suspected when a solid pelvic mass is visualized, separate from the ovaries, and demonstrates a narrow vascular stalk with Doppler flow extending from the uterus to an isoechoic mass (see Fig. 33.18D). These pedunculated masses may "slide" against the ultrasonographic probe.

Given the prevalence of these lesions, up to 70% in Caucasians and up to 80% in women of African ancestry,[95] they may be present and asymptomatic, and thus not causal of the patient's AUB. Myomas are classified as intramural, subserosal, subendometrial, or a combination of these. In the PALM-COEIN classification system, the clinician is required to (1) document the presence or absence of 1 or more myomas; (2) distinguish leiomyomas involving the endometrial cavity (SM) from others (O), because it is generally held that SM lesions are more likely to contribute to the etiology of AUB; and (3) categorize intramural, subserosal, and possible parasitic lesions based on the criteria of Wamsteker and accepted by the European Society of Human Reproduction and Embryology (ESHRE; Fig. 33.20).[96]

The mechanism of how leiomyomata contribute to HMB is not completely understood. There is a fourfold increase in the expression of plasminogen activator inhibitors (PAI), a reduction of antithrombin III and thrombomodulin within the endometrium of women that have fibroid-associated HMB.[97] Leiomyoma secrete transforming growth factor (TGF-β), a cytokine that acts as a stimulator of angiogenesis.[97] The location of myomata plays a role in the likelihood of developing HMB. SM and intrauterine myomas, which increase the endometrial surface area available for withdrawal bleeding, are more commonly associated with HMB.

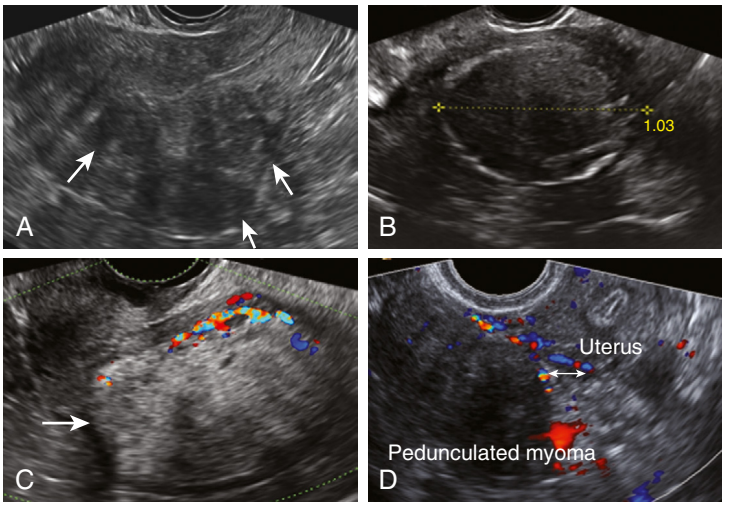


**Fig. 33.18 Uterine fibroids appear as solid, well-defined round lesions within the uterine corpus. (A)** Longitudinal view of the uterus with three hypoechoic myomas with acoustic shadowing in the posterior wall *(arrows)*. **(B)** Transverse view of the uterus with a myoma with a calcified echogenic ring. **(C)** Transvaginal sonography retroverted uterus with a fundal myoma with lipomatous degeneration *(arrow)*. **(D)** A pedunculated myoma with color Doppler flow demonstrating flow contiguous with the uterus *(double-headed arrow)*.

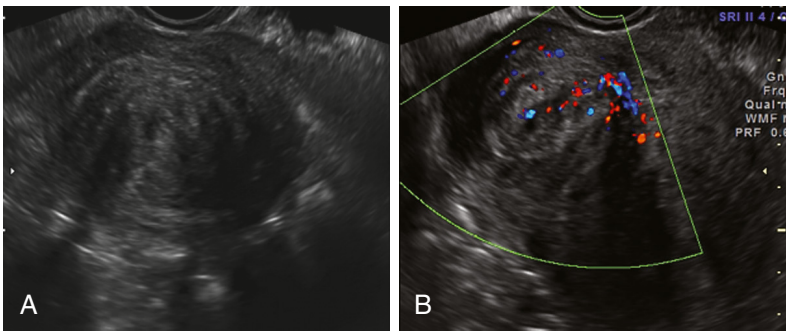


**Fig. 33.19 Myomas typically demonstrate mostly peripheral flow on color or power Doppler. (A)** Transverse view of a uterus with a fundal myoma demonstrating a rounded, well-defined lesion with acoustic shadowing; **(B)** on color Doppler a myoma has diffuse, but mostly peripheral flow.

## Malignancy and Hyperplasia (AUB-M)

Although EC is thought to be a cancer of the postmenopausal years, 14% of cases are diagnosed in premenopausal women; 5% of this group are younger than 40 years.[98] Premalignant hyperplastic and malignant processes of the endometrium arising during the investigation of women of reproductive age with AUB is classified as AUB-M. The PALM-COEIN classification system for AUB-M in reproductive age women did not seek to replace the 1994 World Health Organization (WHO) 1994 and FIGO classification systems for "endometrial hyperplasia and neoplasia."

The 94WHO classification system has been widely used and segregates endometrial hyperplasia by architecture (simple versus complex) and cytology (atypical versus nonatypical). This four-part category system (simple hyperplasia, complex hyperplasia, simple hyperplasia with atypia, and complex hyperplasia) is limited by poor diagnostic reproducibility,[99] the four separate categories do not correspond to distinct biologic entities, and the individual categories do not suggest specific management algorithms. "Endometrial hyperplasia" is a term that has historically been implemented with several qualifiers to encompass both clonal premalignant lesions and benign field effects of the endometrium in response to prolonged and/or excessive estrogen exposure.

In the schema developed by the International Endometrial Collaborative Group, histomorphologic, genetic, clinical, and bio logical data were used to develop quantitative pathologic criteria for three disease categories: (1) benign endometrial hyperplasia, (2) endometrial intraepithelial neoplasia (EIN; premalignant), and (3) endometrial adenocarcinoma, endometrioid type, well-differentiated (malignant; Table e33.4).[100] A diagnosis of EIN is rendered when a lesion has a minimum dimension of 1 mm, the area of glands exceeds the area of stroma, the cytology is changed relative to background, and both benign mimics (polyps, secretory endometrium, and effects of exogenous estrogen) and cancer can be excluded (Table e33.5). It has been demonstrated that clinical outcome prediction and interobserver reproducibility with the EIN classification system are greater than with the 94WHO schema.[101]

True benign endometrial "hyperplasias" are polyclonal proliferations involving endometrial glands and stroma that develop in response to the systemic effects of an abnormal estrogenic stimulus. The morphology of these benign endometrial proliferations changes with duration and dose of exposure and is dependent upon the patient and her medical history. These polyclonal proliferations are categorized in the EIN schema as "benign endometrial hyperplasia."

As the majority of patients with hyperplasia and EC will present with PMB, the imaging characteristics of EIN and endometrial carcinoma will be addressed in the section on PMB.

## Coagulopathy (AUB-C)

Deficiencies in coagulation factors or abnormalities in platelet function are commonly associated with abnormally excessive or prolonged uterine bleeding. Undiagnosed bleeding disorders, in particular von Willebrand disease (vWD) and platelet function disorders, can be an

**ETABLE 33.4** Diagnostic Criteria for Endometrial Intraepithelial Neoplasia

| Nomenclature | Topography | Functional Category | Treatment |
|---|---|---|---|
| Benign endometrial hyperplasia | Diffuse | Prolonged estrogen effect | Hormonal therapy, symptomatic |
| Endometrial intraepithelial neoplasia | Focal progressing to diffuse | Precancerous | Hormonal therapy or surgery |
| Endometrial adenocarcinoma, endometrioid type, well-differentiated | Focal progressing to diffuse | Malignant | Surgery, stage-based |

Modified from Baak JP, Mutter GL, Robboy S, et al. The molecular genetics and morphometry-based endometrial intraepithelial neoplasia classification system predicts disease progression in endometrial hyperplasia more accurately than the 1994 World Health Organization classification system. *Cancer*. 2005;103:2304–2312; and Mutter GL. Endometrial intraepithelial neoplasia (EIN): will it bring order to chaos? The Endometrial Collaborative Group. *Gynecol Oncol*. 2000;76:287–290.

**ETABLE 33.5** Definitions of Endometrial Intraepithelial Neoplasia Criteria

| Endometrial Intraepithelial Neoplasia Criteria | Comments |
|---|---|
| Architecture | Area of glands greater than stroma (volume percentage stroma less than 55%) |
| Cytology | Cytology differs between architecturally crowded focus and background |
| Size greater than 1 mm | Maximum linear dimension exceeds 1 mm |
| Exclude mimics | Benign conditions with overlapping criteria (i.e., basalis, secretory, polyps, repair |
| Exclude cancer | Carcinoma if maze-like glands, solid areas, or appreciable cribriforming |

Modified from Baak JP, Mutter GL, Robboy S, et al. The molecular genetics and morphometry-based endometrial intraepithelial neoplasia classification system predicts disease progression in endometrial hyperplasia more accurately than the 1994 World Health Organization classification system. *Cancer*. 2005;103:2304–2312; and Mutter GL. Endometrial intraepithelial neoplasia (EIN): will it bring order to chaos? The Endometrial Collaborative Group. *Gynecol Oncol*. 2000;76:287–290.